

Video Article

Spatiotemporal Mapping of Motility in *Ex Vivo* Preparations of the Intestines

Derek M. Kendig^{1,2}, Norm R. Hurst¹, John R. Grider¹¹Department of Physiology and Biophysics, Virginia Commonwealth University²Department of Biology, Loyola University MarylandCorrespondence to: Derek M. Kendig at dmkendig@loyola.eduURL: <https://www.jove.com/video/53263>DOI: [doi:10.3791/53263](https://doi.org/10.3791/53263)

Keywords: Molecular Biology, Issue 107, Spatiotemporal map, diameter map, gastrointestinal tract, propulsion, peristalsis, motility, video-recording, STmap, Dmap

Date Published: 1/27/2016

Citation: Kendig, D.M., Hurst, N.R., Grider, J.R. Spatiotemporal Mapping of Motility in *Ex Vivo* Preparations of the Intestines. *J. Vis. Exp.* (107), e53263, doi:10.3791/53263 (2016).

Abstract

Multiple approaches have been used to record and evaluate gastrointestinal motility including: recording changes in muscle tension, intraluminal pressure, and membrane potential. All of these approaches depend on measurement of activity at one or multiple locations along the gut simultaneously which are then interpreted to provide a sense of overall motility patterns. Recently, the development of video recording and spatiotemporal mapping (STmap) techniques have made it possible to observe and analyze complex patterns in *ex vivo* whole segments of colon and intestine. Once recorded and digitized, video records can be converted to STmaps in which the luminal diameter is converted to grayscale or color [called diameter maps (Dmaps)]. STmaps can provide data on motility direction (*i.e.*, stationary, peristaltic, antiperistaltic), velocity, duration, frequency and strength of contractile motility patterns. Advantages of this approach include: analysis of interaction or simultaneous development of different motility patterns in different regions of the same segment, visualization of motility pattern changes over time, and analysis of how activity in one region influences activity in another region. Video recordings can be replayed with different timescales and analysis parameters so that separate STmaps and motility patterns can be analyzed in more detail. This protocol specifically details the effects of intraluminal fluid distension and intraluminal stimuli that affect motility generation. The use of luminal receptor agonists and antagonists provides mechanistic information on how specific patterns are initiated and how one pattern can be converted into another pattern. The technique is limited by the ability to only measure motility that causes changes in luminal diameter, without providing data on intraluminal pressure changes or muscle tension, and by the generation of artifacts based upon experimental setup; although, analysis methods can account for these issues. When compared to previous techniques the video recording and STmap approach provides a more comprehensive understanding of gastrointestinal motility.

Video Link

The video component of this article can be found at <https://www.jove.com/video/53263/>

Introduction

Various methods of recording and analyzing intestinal motility have been developed over the past 150 years¹. These have ranged from the initial *in vivo* observations and descriptions of William Beaumont and of Walter Cannon to the more recent methods of measurement and interpretation of multisite recording of muscle tension, intraluminal pressure, and/or membrane potential (*i.e.*, junctional potentials)²⁻⁶. These latter approaches provide a snapshot of overall motility patterns, but are limited by the number of sites of recording and the validity of interpolation of the data to areas in between the recording sites.

The recent development of video recording and spatiotemporal mapping (STmap) techniques have made it possible to observe and analyze complex motility patterns in *ex vivo* whole segments of colon and intestine. Initial approaches, first described for intestinal segments in the late 1990s^{7,8}, depended on investigator-designed software to analyze video recording; several groups have now created or modified software for this purpose^{2,8-12}. While many groups have generated their own software packages or plugins, they all analyze diameters of a tissue segment and convert those various diameters to grayscale representation. A commercially available recording and analysis system called the Gastrointestinal Motility Monitoring system (GIMM) provides a turnkey approach that allows for analysis of both propulsive motility via fecal pellet velocity determination in the guinea pig distal colon¹³ as well as analysis of propulsive and mixing motility patterns with a fluid stimulus in intact intestinal segments^{4,5,14-19}. This latter approach depends on the generation and analysis of STmaps and is described in this paper. The goal of this method is to increase the ability to qualitatively and quantitatively analyze various motility patterns present in the intestine. While other groups have used the STmap for motility analysis through their own software, this is the first description of how to use the GIMM to analyze motility patterns by generation of STmaps. In the present paper, we provide detailed step-by-step instructions on: the preparation of gut tissues for video recording, proper setting of video recording parameters to maximize ability to detect changes in tissue diameter, the creation of STmaps, as well as the interpretation and analysis of the STmaps using the GIMM system and ImageJ software.

The method described here is specific to analysis of the luminal perfusion of fluids or semi-solids containing compounds which affect intestinal motility patterns. A method for analysis of fecal pellet propulsion is described in a paper by Mawe and colleagues¹³. The general method described here could be applied to other tubular smooth muscle organs such as: the small intestine, blood vessels, urethra, ureters, *etc.*

While this method on its own does not provide data on changes in pressure or muscle tension, it could be coupled with the use of pressure transducers, force transducers or electrophysiological measurements to provide a more complete picture of the motility patterns as some other groups have shown^{2,15,20,21}.

Protocol

Virginia Commonwealth University's Institutional Animal Care and Use Committee (IACUC) approved all animals and euthanasia procedures used in this protocol.

1. Preparation of Solutions

1. Prepare 4 L of Krebs buffer (composed of [in mM]: 118 NaCl, 4.75 KCl, 1.19 KH₂PO₄, 1.2 MgSO₄, 2.54 CaCl₂, 25 NaHCO₃, 11 glucose). Weigh out the appropriate amounts of each solid chemical, put into the appropriate volume of deionized water and mix using a vortex until the solution is clear.
2. Then, aerate the solution with carboxygen (95% O₂, 5% CO₂) for 30 min while heating to 37 °C.
3. Determine the pH of the solution while at 37 °C (the same temperature as in the organ bath) and adjust to pH 7.4 if necessary using HCl. Keep the Krebs buffer continuously carboxygenated and at 37 °C throughout the length of the experiment.
4. Put the inflow and outflow tubes from the peristaltic pumps into the buffer reservoir and turn on the peristaltic pumps to begin perfusion of the buffer throughout the tubing and organ bath system.
NOTE: Buffer may initially be pumped back into the original container until the addition of either tissue into the organ baths or chemicals into the perfusion buffer. This reduces the total amount of buffer required for experimentation. Then the outgoing buffer perfusion lines should be placed into an empty container so that the ingoing and outgoing buffers do not mix.
5. Calibrate the temperature of the heating system on the bath circulator so that the buffer within the organ baths becomes and remains 37.0 ± 0.5 °C for the duration of the experiment. Confirm, and modify if necessary, the pH of the Krebs buffer at least one more time before placing tissue segments in the bath in step 2.8.

2. Preparation of Tissues

1. Euthanize a guinea pig by use of carbon dioxide inhalation/asphyxiation in a sealed chamber or another euthanasia method approved by the local animal care and use committee.
2. After confirming euthanasia of the animal, cut open the abdominal wall longitudinally with dissection scissors and locate the intestines. Cut the mesentery attached to the small intestine to help expose the cecum.
NOTE: To confirm euthanasia perform a secondary procedure such as bilateral thoracotomy as approved by an animal care and use committee.
3. Locate the distal end of the cecum and transect the proximal colon just distal to its connection to the cecum. Then transect the proximal colon again ~ 8 cm distal to the first transection.
4. Place the colon tissue into warmed and carboxygenated Krebs solution (described in section 1) for further dissection. Pin the colon into the dissection bath and use a smaller set of scissors to remove as much mesentery and fat as possible.
5. In the heated dissection tray, remove all intraluminal content by gently perfusion of Krebs buffer through the lumen using a syringe coupled to a blunt end catheter (to help prevent perforation of the tissue). Avoid over-distension of the segment during this perfusion process.
6. Obtain two fire-polished glass tube catheters (3-mm diameter) and place a short piece of polyethylene tubing (~ 3 mm long and ~3 mm diameter) around the portion of the glass tube entering the tissue lumen.
NOTE: This will allow the suture to be placed around the tissue and glass tube to remain secure and not slip as the preparation is placed into the organ bath and during changes in tissue length.
7. Insert one catheter into the oral end of the tissue preparation and tie a suture around the small piece of tubing surrounding the catheter using a surgeon's knot. Gently attempt to pull the catheter back out to ensure the knot is snug. Then, perform the same action on the other catheter entering the aboral end of the tissue.
8. Once the catheters are secured, move the entire preparation (tissue plus catheters) from the dissection tray into one of the organ baths. Place the preparation into the bath with the oral end facing away from the user.
9. Next mount/secure the glass tube catheters to the organ bath by one of the two suggested methods.
NOTE: Securing the glass tubes prevent the tissue segment from changing length during the experiment or coming above the surface level of the Krebs buffer in the bath.
 1. Option A: Secure the top portion of the glass tube to the top of the side of the plastic organ bath through the use of molder's clay or a plastic clip.
 2. Option B: Secure the glass tubes to the metal poles that hold the cameras above the organ bath preparation by use of plastic clips.
10. Once the catheters are secured to the bath, attach a 5-cm piece of tubing to the open end of each catheter. For the oral catheter, attach this tubing to a 10-ml syringe, which will be used to inject buffer into the lumen of the proximal colonic segment. For the aboral catheter, this piece of tubing will allow the luminal outflow to be directed into a collection container (50 ml beaker, reservoir, etc.).
11. Using the syringe attached to the oral end, slowly flush warmed Krebs buffer through the tissue lumen to ensure that liquid can flow through the tissue. Flow is confirmed by liquid exiting the aboral catheter. Calibrate the video-recording system (protocol section 3) while the tissue equilibrates for 30 min.

3. Calibration of Video-recording System

1. Calibrate the camera height placement, video settings for brightness and contrast, and horizontal distance using the software.
NOTE: The best settings for intraluminal perfusion setups are different than the settings used to determine velocity of pellet propulsion¹³.

2. Click on the experiment tab for the camera to be calibrated. Then in the 'File' menu click 'Calibrate.'
3. Once the video appears in the 'calibrate workstation' window, set the camera at a height where the image includes the ends of the catheters inserted into the colonic lumen.
4. Then, calibrate the horizontal distance viewed in the image using the translucent ruler sticker attached to each bath.
NOTE: This calibration is crucial to later software calculations of luminal diameter and speed of contractile waves.
5. In the same 'calibrate workstation' window, set the red vertical guidelines so that they are 10 mm apart according to the ruler in the camera image. Then, type the appropriate distance (10 mm) into the 'distance cursors' window and click the 'CAL' button.
6. Next, adjust the gain, brightness, and shutter sliders within the 'calibrate workstation' window to modify the camera image so that the tissue segment appears as a dark silhouette on a light background.
NOTE: **Figure 4** shows good and bad examples of this calibration procedure.
7. To properly adjust the image, also adjust the focus and aperture knobs on the camera itself.
8. Calibration is now complete. Click 'Save', then click 'OK' in the pop-up, and finally click the 'EXIT' button.

4. General Experimental Procedures

1. After camera calibration procedures and 30 min of tissue equilibration are complete, name the trials in each experimental protocol. Trial names can be based on the name and concentration of the compound and volume of liquid being intraluminally perfused into the tissue segment during that portion of the experiment.
2. Then, occlude the tube protruding from the aboral catheter through the use of a tubing clamp.
NOTE: This prevents luminal liquid from exiting the aboral end during further experimentation, allowing the use of specific volumes in the lumen to provoke various levels of distension (**Figure 1**).
3. Inject approximately 0.7 ml of Krebs buffer in the proximal colonic lumen to provide enough distension to initiate propulsive contractions in the guinea pig *ex vivo* preparation.
NOTE: This volume may vary slightly (0.1 - 0.2 ml) depending on the overall length of the intact segment and the amount of stretch applied to the segment in the organ bath.
4. Once the segment is distended by luminal fluid, turn on the camera and then record the motility for a pre-determined period of time (e.g., 10 min).
 1. Specifically, double-click the appropriately named trial to open the experimental camera view and then click the toggle switch to the "ON" position to view the camera field. Then, click the record button to initiate recording (record button will remain red while the camera is recording) and click the record button again to stop recording.
5. At the end of this initial control distension trial, loosen/remove the clamp occluding the aboral catheter to allow the tissue segment to propel the distending liquid out of the lumen.
6. After a 10 min re-equilibration period, repeat this procedure with any of a variety of nutrients, bioactive agents, drugs, or agonists/antagonists in the luminal fluid to modify the propulsive motility of the segment (e.g., short chain fatty acids or decanoic acid)^{10,18}.
 1. To help gauge when the new experimental fluid enters the colonic segment, leave an air bubble near the port of the syringe so that upon perfusion of the new solution into the colonic lumen the progress of the bubble will allow the user to know when the experimental fluid has reached the lumen.
 2. Continue intraluminal perfusion with the aboral catheter open until the bubble has been pushed completely through the luminal perfusion system (may require 2-3 ml of perfusate). Then, allow the tissue segment to expel fluid through the open aboral catheter for up to 5 min.
NOTE: After this procedure, the lumen will contain a negligible volume of fluid, allowing perfusion of a known volume of liquid into the lumen.
7. Re-occlude the aboral luminal catheter tube using a tubing clamp (as in step 4.3) inject the same volume of distending fluid as in the control condition through the syringe. Record the motility patterns during the experimental period for later analysis and comparison to the control Krebs condition (as in step 4.5).
8. Repeat sections 4.4 - 4.7 of the protocol with different luminal compounds or different concentrations of the same luminal compound.

5. Construction of Spatiotemporal Maps (STmaps)

1. After completion of recording the experiment, double-click the name of a specific trial to open the analysis window for construction of an STmap.
2. Within the video playback area, adjust the contrast and brightness sliders in the analysis window to make the image appropriate for analysis (black tissue silhouette on light background; **Figure 4**).
NOTE: If the camera calibration was not performed appropriately before beginning the experiment the image can only be modified to a lesser extent at this point.
3. Once the image is contrasted properly, set the horizontal and vertical red guidelines within the video image window to isolate the tissue region for analysis and remove areas containing artifacts. Also, select the appropriate time segment from the recording by determining the start and stop time points for analysis.
 1. Specifically, select the starting and ending points within the video using the green 'A' and yellow 'B' buttons within the analysis software. Set the time slider to the beginning of the video segment to analyze and then click the green 'A' button. Then, set the slider to the end of the segment to analyze and click the yellow 'B' button.
4. Next, click the 'motor analysis' tab to open the STmap window and click the 'stopwatch' button. After clicking the stopwatch, next click the crosshairs cursor within the black silhouette of the tissue within the recorded movie to begin STmap generation.
5. After clicking the crosshairs in the tissue silhouette, the software generates and displays the STmap for that region of video.
NOTE: This may take a few minutes depending on the length of video selected for analysis.
6. Click 'zoom' to view an enlarged image of the STmap and controls to adjust the image.

1. Click the 'color' option in the newly created window to view the STmap as color instead of grayscale. Also, click the 'Enable' option to be able to place a cursor on specific pixels within the map and view a tracing of the change in luminal diameter for that specific tissue region. Click 'Exit' when finished.
7. Export an STmap for use in papers or presentations or to analyze further in ImageJ by selecting the 'File' menu, followed by selecting 'Export Data' and then 'Meta File'. Then name the STmap, which will be saved as an .emf file and click the 'Save' button.
8. Alternately, save images of the STmap by capturing a screenshot. This is necessary to save pseudo-color versions of the STmap.

6. Analysis of Contractile Wave Velocity in STmaps

1. To analyze the velocity of contractile propagation or contraction duration, first convert the STmap .emf file to .tiff, .gif, .jpg, or .bmp formats that are acceptable to ImageJ through a file conversion program of choice.
NOTE: ImageJ does not open the .emf format output of the STmaps from the software.
 1. Alternatively, use screenshot capture software to take a picture of an STmap on the screen and save it in an appropriate file format.
2. Then open the re-formatted STmap in ImageJ and then open the GIMMProcessor plugin by opening the "Plugins" menu and selecting 'GIMMProcessor'. This will open both 'GIMMProcessor' and 'Measurements Table' windows.
3. Click the 'rectangular selection tool' within the ImageJ window and then use it to outline by clicking and dragging the entire area of the scalebar in the upper right corner of the STmap. After that region is selected, click the 'set calibration' button in the plugin. Finally, insert the appropriate distance (mm) and time (sec) into the calibration box according to the values on the scalebar and click 'Done'.
4. Next, click the line drawing tool in the ImageJ window. Draw a line on the STmap through the center of a propagating contraction along the angle of the slope by clicking and dragging on the STmap image. Alternately, draw a vertical line through a band of non-propagating contraction to determine contraction duration.
5. After the line is drawn appropriately (only one line may be drawn at a time), click the 'take measurement' button in the plugin to generate a read-out of the horizontal distance, vertical distance, and slope of the line; which correspond to length (mm), time (sec), and velocity (mm/sec) respectively. This data is displayed in the 'Measurements Table' window.
6. Repeat the line drawing and analysis steps multiple times within a given STmap and save the data as a .gmd file. Click the 'Save' button in the plugin and name the file. Then click 'Save' again to complete the process. These data can later be compared with other trial data or used to re-draw lines on an STmap.

Representative Results

Understanding Spatiotemporal Maps (STmaps) as Diameter Maps (Dmaps)

While the maps generated by this technique are spatiotemporal, change in the luminal diameter of the tissue is the parameter specifically visualized in both distance and time. The STmap portrays horizontal distance along the tissue segment on the x-axis (in mm) and time on the y-axis (in sec) with the starting time at the top and ending time at the bottom. In the upper right corner is a legend, which displays minimum and maximum luminal diameters as well as scaling for both the x and y-axes (**Figures 1-4**). Thus, different pixel shades within the grayscale image correspond to different luminal diameters. Darker pixels correspond to wider diameters and lighter pixels correspond to smaller diameters. Thus, contractile waves of the circular muscle will appear as regions of lighter pixelation due to the reduction in luminal diameter (**Figure 1** black arrows). In contrast, luminal distension due to circular muscle relaxation or a large bolus of fluid will cause an increase in luminal diameter and darker pixels in the STmap/Dmap (**Figure 1C** white arrows). A further discussion of the formation and meaning of STmaps can be found in a paper by Lammers group¹¹.

Luminal Distension-Induced Propagating Contractions

In **Figure 1**, guinea pig proximal colon was distended with 0.5, 1.0, 1.5, and 2.0 ml of Krebs buffer for 5 minutes at each volume. Propagating contractions were elicited by all volumes ≥ 1.0 ml and appear as thin white bands in the STmap (**Figure 1**). Distension of the intestinal lumen causes the initiation of propagating contractions. As shown in **Figure 1**, the diameter of the lumen increases with greater intraluminal volumes and the pixels in the STmap corresponding to that diameter become darker creating an overall darker background. At some level of distension the peristaltic reflex is activated (1.0 ml; **Figure 1**), which initiates propulsive waves of contraction at the oral end that decrease the diameter of the lumen and move towards the anal end of the segment (shown as a white bands in **Figures 1** and **4**). The white band representing contraction is often preceded by a dark band, which represents the aboral relaxation ahead of the peristaltic wave (**Figure 1C** white arrows). These white and dark pixels correspond to the ascending contraction and descending relaxation components of the peristaltic reflex, respectively^{22,23}. In the STmap in **Figure 1** panel A, there are 0 propulsive waves at 0.0 ml, 0 propulsive waves at 0.5 ml distension, 3 propulsive waves at 1.0 ml distension, 6 propulsive waves at 1.5 ml distension, and 5 propulsive waves at 2.0 ml distension.

Nutrient-Induced Stationary/Mixing Contractions

Waves of propagating contraction are not the only motility pattern that can be visualized by STmaps. Mixing patterns of motility such as segmentation can also be seen in STmaps and the corresponding image (**Figure 2A**). This pattern is different than propagating contractions. During mixing patterns many small, stationary contractions occur in different areas at the same time (visualized as multiple small white squares in the same horizontal line, but not touching each other). While each segmental contraction is stationary and does not move in the oral to anal manner as described for propagating contractions, the ability of the STmaps to illustrate complex contractile patterns over long time periods allows visualization of the slow progression of contractions anally over time (**Figure 2A** black arrow). The duration of each individual contraction can also be determined by drawing a vertical line through the white contraction square using ImageJ and the associated plugin (**Figure 2A**). In this particular STmap generated from intra-colonic perfusion of short chain fatty acids, the average stationary contraction duration is ~ 2 sec (range: 1.9 to 2.1 sec). While mesentery remaining on a tissue segment can cause artifacts in analysis, the vertical line artifacts generated by mesentery (**Figures 1B, 2B**) can be used to determine longitudinal muscle movements. In **Figures 1B** and **2B** the horizontal movement of the

black vertical line is due to contraction and relaxation of longitudinal muscle. This lateral movement of longitudinal muscle can be visualized on STmaps as horizontal movements of the vertical bands generated by mesentery artifacts (**Figures 1B, 2B**).

ImageJ and Plugin Analysis of STmaps

Both the velocity of a propagating wave (**Figure 3**) as well as duration of contraction (**Figure 2**) can be determined by using ImageJ and the GIMMProcessor plugin. In **Figure 3**, the velocity of propagation of both orthograde and retrograde waves was ~ 0.25 mm/sec (range: 0.21 to 0.35 mm/sec). As can be seen in the video image above the ST map, the analysis lines (red lines forming a box on the video image) were set precisely around one edge of the tissue segment instead of around the entire segment. This is an important use of the guidelines in the software. Precise setting of these guidelines is crucial to proper analysis of the video as further analyzed in the discussion section. This allows the generation of an STmap that visualizes myogenic ripple contractions²⁴. These contractions are myogenic in origin and do not change luminal diameter greatly. Also, different directions of propagation (orthograde or retrograde), which are common for ripples, can be analyzed using this technique (**Figure 3**). As shown in **Figure 2** the duration of contraction can vary in different regions of the tissue segment.

Proper Analysis of STmaps

One potential issue with the creation of STmaps is possible artifact generation due to the experimental methodology. For instance, mesentery left on the outside of the tissue will increase the diameter reading for that segment of the tissue creating a vertical black line on the STmap (**Figures 1, 2B**). The presence of mesentery also artificially broadens the grayscale map by increasing the widest luminal measurement, which results in a blunting of the contrast measurements of the scale. For this reason it is best to remove the mesentery as completely as possible from the segment without perforating the tissue. Another possible STmap artifact is a white vertical line due to bubbles within the luminal fluid that cannot be contrasted to black (**Figure 4B**). These bubbles may make the luminal diameter appear smaller to the analysis software or overlay white/light regions on the motility patterns in the STmap. Therefore, setup of the tissue segment and proper contrasting of the video recording before analysis are absolutely crucial to success in constructing STmaps (**Figure 4**). Proper and improper contrasting setups are shown in **Figure 4**. It is important to note that video adjustment in both the pre-experiment camera calibration and post-experiment analysis window are crucial to proper STmap generation and analysis. Improper image calibration can lead to STmaps with unusable data (**Figure 4A**).




Figure 1. Propagating Waves in the Proximal Colon. (A) A distension-response curve (performed in guinea pig proximal colon) was used to determine the appropriate intraluminal fluid volume to initiate propagating waves in this segment (white horizontal bands). Black arrows illustrate examples of full-length propagating waves. White arrows illustrate the line artifact caused by incomplete mesentery removal. **(B)** A closer view of propagating contractions achieved by STmap generation from an experiment similar to Panel A, but a video of shorter duration. It is easier to note that the contractions progress in the oral to anal direction and to identify the preceding aboral relaxation represented as a dark area ahead of the white band compared to panel A. This map also provides another view of mesentery artifacts. The red box identifies the region of this STmap expanded in Panel C. **(C)** This panel illustrates an even closer view of the same video and map as in panel B. White arrows labeled 'Fluid Distension' point to dark pixels that are due to luminal distension by fluid aboral to the propagating wave. These are regions where circular muscle relaxation occurs aboral to circular muscle contraction. Note that the propagating contractions look like completely horizontal lines in panel A due to the long timescale of the map. In panels B and C the time scales are progressively shorter so that the contractile wave has a slope that can be measured and reported as the velocity of the wave movement. [Please click here to view a larger version of this figure.](#)




Figure 2. Determination of Contraction Duration by STmap. (A) Guinea pig proximal colon shows a mixing/segmental motility pattern in response to intraluminal perfusion of short chain fatty acid (butyrate). Vertical red lines have been drawn through the periods of contraction to determine contraction duration using Image J and the GIMMProcessor plugin. The black arrow shows the aboral direction of propagation of the stationary contractions. (B) Propagating contractions in mouse ileum often show regions of sustained contraction. Vertical arrows drawn on this map show that more oral regions remained contracted for a longer duration. In this preparation, the anal end of the preparation was closed to prevent fluid from leaving the closed system during tissue contractions. The image at the top of the panel shows a time when the entire oral end of the tissue is contracted (white on STmap), while the entire anal end is distended by fluid (black on STmap). The horizontal/lateral movement of the vertical black in the middle of the Panel B STmap shows movement of the longitudinal muscle layer. [Please click here to view a larger version of this figure.](#)

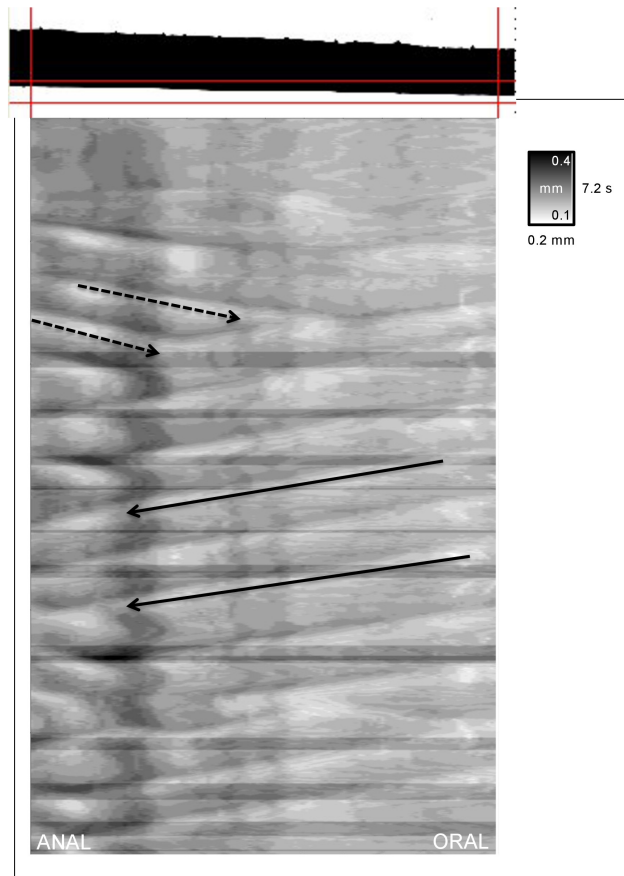


Figure 3. Bi-Directional Motility Patterns. Propagating waves can move in both orthograde (oral to anal) and retrograde (anal to oral) directions. Solid black arrows show normal orthograde propagation and dashed black arrows show retrograde propagation. The velocity of propagation of both orthograde and retrograde contractions in this STmap were determined by ImageJ analysis and were ~ 0.25 mm/sec. Image analysis lines (red lines forming a box on the video image above the STmap) were set close to one edge of the tissue to visualize myogenic ripple contractions which are low amplitude, shallow contractions often oriented in orthograde, retrograde, or both directions. [Please click here to view a larger version of this figure.](#)




Figure 4. Importance of Proper Image Contrast for STmap Generation. (A) shows an improperly contrasted image and STmap, while panel B shows a properly contrasted image and STmap. In (A) the horizontal white bands generated from the properly contrasted image (B) are not as obvious and there are multiple artifacts (white shading) due to the initial image being in grayscale. In the STmap generated from the properly contrasted image (B) the white shading artifacts of the grayscale disappear and the propagating waves are more pronounced. Also, the black shading representing relaxation ahead of the propagating contractile wave can be seen in the anal end of the STmap with each wave of contraction. In panel B the white arrows illustrate an STmap artifact generated by a region of the image that could not be properly contrasted. This type of artifact is mostly due to intraluminal bubbles that occasionally occur in the preparation during the course of the experimental protocol. [Please click here to view a larger version of this figure.](#)

Discussion

Intestinal motility has been viewed and described from a number of perspectives based on the nature of the parameters being recorded. Video recording and spatiotemporal mapping has proven a valuable tool that allows analysis of overall movement and/or propulsion over long segments of gut as well as analysis of activity at specific points along the segment. The approach taken to video recording and spatiotemporal mapping can be twofold and is reflective of the region examined and the nature of the luminal contents. In intestinal segments where luminal contents are more fluid and in proximal colon where contents are more semi-solid, activity is induced by intraluminal introduction of fluid by bolus or infusion. Spatiotemporal maps made from these video records are designed to represent the movement of the whole segment as described above. In contrast, in the mid- to distal colon where the contents are more solid, activity is initiated by insertion of a fecal pellet (epoxy coated natural pellet or artificial pellet) and spatiotemporal maps are designed to reflect the movement of the pellet through the colon as illustrated in the JOVE article of Hoffman *et al.*¹³. Thus the setup of the experiment and analysis are crucial and depend upon the type of stimulus and the region being studied. Therefore, the critical steps for generation and analysis of spatiotemporal maps of fluid-induced intestinal motility are: 1) proper removal of mesentery from the dissected tissue; 2) proper image calibration before recording; 3) proper removal of artifacts during STmap generation and analysis; 4) proper setup of the analysis system; and 5) gaining the manual dexterity to catheterize and suture the segments without damaging them.

While the use of STmaps of luminal diameter have improved the ability to visualize and analyze full motility patterns over a region of intestine, the technique is best used when coupled with functional measurements of pressure or muscle contraction^{2,15,20}. For instance, while some muscle contractions may change luminal diameter slightly and be visible on some STmaps (*i.e.*, myogenic ripples) they may not actually cause any propulsion or mixing of intestinal contents²⁵. This cannot be known without coupling of this technique to other functional measurements. Also, the nature of many tissue preparations in this type of system (*i.e.*, a closed luminal system or constant luminal perfusion by a pump system) leads to artifacts within STmaps. Thus, the user must be aware of how their specific organ preparation and experiment can lead to artifacts in the data and ways to avoid or exclude these artifacts in data analysis (*e.g.*, mesentery-induced vertical lines or dark pixelation due to the tissue's inability to expel fluid from the system in a closed luminal preparation). There are multiple methods for luminal perfusion of an intact intestinal

segment besides a closed system. One method is to instead use an open system that maintains a constant intraluminal/back pressure through the use of a raised tube and/or one-way valve on the anal end of the preparation^{8-10,30}. This allows the fluid to move out of the preparation during propulsive contractions.

As the system is setup mainly to detect changes in luminal diameter, those contractions or motility patterns that do not greatly affect luminal diameter are often difficult to visualize by this protocol. Since changes in the pixel shading within the STmap are based on changes in luminal diameter, motility patterns that do not cause large changes in diameter will not be visualized well in this method if strong contractions are also present within the same recording. As described for the visualization and analysis of ripple-type contraction (**Figure 3**), setting the analysis lines in the video recording closer to the tissue wall can obviate this issue. This method reduces the maximal diameter displayed within the STmap, so contractions that only minimally change tissue diameter can be visualized. Another option to solve this issue is changing the duration of the video segment analyzed, to exclude contractions which greatly affect luminal diameter, so that smaller contractions are more easily visualized. This leads to the potential problem of motility that minimally changes luminal diameter looking similar to a separate STmap where contractions greatly changed luminal diameter. This is because the determination of white pixels on the map is based on the smallest diameter in a given video. If there is not much variability in diameter within the video (little or no contraction of the circular muscle) very small contractions that do not change the diameter of the preparation greatly can look similar to peristaltic contractions from another video. Therefore, it is important to consider the figure legend in the upper right corner of the map. If the difference between the maximum and minimum diameters is small it is important to compare the STmap to the video it was generated from to determine the validity of the pixel shade change as represented in the STmap. Thus, examination of the scale bar in conjunction with the actual recording is critical to correct interpretation of the map.

Video recording and spatiotemporal mapping of intestinal and colonic segments have been applied to a variety of species including zebrafish²⁶, mouse^{25,27-30}, rat^{7,9,30-33}, guinea pig^{5,6,8,13-19,24,30,32,34,35}, brushtail possum^{12,36}, rabbit^{2,30,37,38}, chicken³⁹, pig^{40,41} and human⁴². The most widely studied species is the guinea pig. This is not surprising because the guinea pig enteric nervous system has been most completely characterized and historically it has been the animal most studied *in vitro* with regard to propulsive motility of the intestine⁴³. Spatiotemporal mapping has been mostly applied to tubular segments of gut from small animals; however, studies in the rabbit and pig using modified systems demonstrate the application of this methodology to larger animals. In the case of the rabbit, the approach is identical to that of smaller animals except that larger segments and organ baths were used³⁰. The approach used in the pig was to use an exteriorized loop of intestine from an anesthetized pig rather than immersion of a dissected tissue segment into an organ bath. Also, STmaps were generated by cross-correlation rather than the transillumination method used in most studies⁴⁰. The isolated, vascularly perfused loop preparation for video recording and spatiotemporal mapping has also been applied to smaller species such as rat³³. A recent study by Kuizenga *et al.* is the first use of STmaps of video recorded motility patterns in *ex vivo* segments of human intestine⁴², although, STmapping approaches have been applied to the analysis of manometric (pressure) recordings in humans *in vivo*^{3,44}. The recorded motility patterns in human tissue are similar to those already recorded in animal models using similar techniques and validate the extension of this approach to human tissues. It is noteworthy that this study combined STmaps derived from video recordings with measurement of muscle contraction recorded by force transducers. Measurement of intraluminal pressure by a fiber optic manometric catheter inserted into the *ex vivo* segment was also converted into an STmap, showing the versatility of the STmap to visualize more than changes in luminal diameter. This combined approach correlating muscle tension, intraluminal pressure and wall movement allows for a more in-depth functional analysis of the STmaps generated from the video record.

Studies of STmaps generated from wall movements and changes in luminal diameter (also called Dmaps) have allowed detailed descriptions of motility patterns such as propulsive peristaltic waves and localized segmental contractions. While these patterns were identified by earlier experimental methods, the current approach allows a more refined definition of localized contractile movements such as ripples and novel anti-peristaltic contractions^{9,24,25,30,31,42}. The construction of STmaps and analysis of changes in motility pattern have been applied to key questions in the gastrointestinal motility of intestine and colon. These include: differentiation of neurogenic and myogenic contractions and defining the role of interstitial cells of Cajal^{6,9,11,12,16,24,26,27,29-31,33,37-40,42}, understanding the complex interactions between the circular and longitudinal muscle layers^{2,7,8,11,12,32,39,40}, examining the effects of intraluminal nutrients^{10,18,19}, microbial strains³⁴, and viscosities^{12,36} on various motility patterns, and understanding the role of various endogenous neurohormonal agents and exogenous pharmacological agents^{2,4-7,9,10,13-17,28,35,40} in the generation and modification of motility. The future of this technique involves coupling it with other measurements including pressure, electrophysiology and tension/contractility. Recent studies have often incorporated one or more of these measurements in conjunction with video recording and spatiotemporal mapping to provide additional correlative details^{2,42}. Moreover, the system can be used to measure motility in other tubular and non-tubular organs. For instance, attempts have been made at measuring gastric motility using such a system but the technique and software need refinement to better quantify motility in such a non-tubular organ⁴⁵. There is no doubt that the use of spatiotemporal mapping techniques alone and in combination with more traditional methods of analysis will lead to a more in-depth and comprehensive understanding of gastrointestinal motility in the future.

Disclosures

Catamount Research and Development, Inc., creator of the GIMM system, covered publication fees for this manuscript.

Acknowledgements

DMK was supported by an IRACDA grant from NIGMS (K12GM093857) to Virginia Commonwealth University. This work was supported by NIDDKD grant DK34153 to John R. Grider.

References

1. Szurszewski, J. H. A 100-year perspective on gastrointestinal motility. *Am. J. Physiol.* **274** (3 Pt 1), G447-53 (1998).
2. Dinning, P. G., Arkwright, J. W., *et al.* Temporal relationships between wall motion, intraluminal pressure, and flow in the isolated rabbit small intestine. *Am. J. Physiol. Gastrointest. Liver Physiol.* **300** (4), G577-85, (2011).

3. Dinning, P. G., Zarate, N., *et al.* Pancolonic spatiotemporal mapping reveals regional deficiencies in, and disorganization of colonic propagating pressure waves in severe constipation. *Neurogastroenterol. Motil.* **22** (12), e340-9, (2010).
4. Hoffman, J. M., McKnight, N. D., Sharkey, K. A., & Mawe, G. M. The relationship between inflammation-induced neuronal excitability and disrupted motor activity in the guinea pig distal colon. *Neurogastroenterol. Motil.* **23** (7), 673-e279, (2011).
5. Wood, M. J., Hyman, N. H., & Mawe, G. M. The effects of daikenchuto (DKT) on propulsive motility in the colon. *J. Surg. Res.* **164** (1), 84-90, (2010).
6. Smith, T. K., Oliver, G. R., *et al.* A smooth muscle tone-dependent stretch-activated migrating motor pattern in isolated guinea-pig distal colon. *J. Physiol.* **551** (Pt 3), 955-69, (2003).
7. Benard, T., Bouchoucha, M., Dupres, M., & Cugnenc, P. H. *In vitro* analysis of rat intestinal wall movements at rest and during propagated contraction: a new method. *Am. J. Physiol.* **273** (4 Pt 1), G776-84 (1997).
8. Hennig, G. W., Costa, M., Chen, B. N., & Brookes, S. J. Quantitative analysis of peristalsis in the guinea-pig small intestine using spatio-temporal maps. *J. Physiol.* **517** (Pt 2), 575-90, (1999).
9. Chen, J.-H. H., Zhang, Q., *et al.* Neurogenic and myogenic properties of pan-colonic motor patterns and their spatiotemporal organization in rats. *PLoS One.* **8** (4), e60474, (2013).
10. Gwynne, R. M., Thomas, E. A., Goh, S. M., Sjövall, H., & Bornstein, J. C. Segmentation induced by intraluminal fatty acid in isolated guinea-pig duodenum and jejunum. *J. Physiol.* **556** (Pt 2), 557-69, (2004).
11. Lammers, W., & Cheng, L. Simulation and analysis of spatio-temporal maps of gastrointestinal motility. *Biomed. Eng. Online.* **7**, 2, (2008).
12. Lentle, R. G., Janssen, P. W., Asvarujanon, P., Chambers, P., Stafford, K. J., & Hemar, Y. High definition mapping of circular and longitudinal motility in the terminal ileum of the brushtail possum *Trichosurus vulpecula* with watery and viscous perfusates. *J. Comp. Physiol. B.* **177** (5), 543-56, (2007).
13. Hoffman, J. M., Brooks, E. M., & Mawe, G. M. Gastrointestinal Motility Monitor (GIMM). *J. Vis. Exp.* (46), (2010).
14. Krauter, E. M., Strong, D. S., Brooks, E. M., Linden, D. R., Sharkey, K. A., & Mawe, G. M. Changes in colonic motility and the electrophysiological properties of myenteric neurons persist following recovery from trinitrobenzene sulfonic acid colitis in the guinea pig. *Neurogastroenterol. Motil.* **19** (12), 990-1000, (2007).
15. Spencer, N. J., Nicholas, S. J., *et al.* Mechanisms underlying distension-evoked peristalsis in guinea pig distal colon: is there a role for enterochromaffin cells? *Am. J. Physiol. Gastrointest. Liver Physiol.* **301** (3), G519-27, (2011).
16. Sia, T. C., Brookes, S. J., Dinning, P. G., Wattchow, D. A., & Spencer, N. J. Peristalsis and propulsion of colonic content can occur after blockade of major neuromuscular and neuromuscular transmitters in isolated guinea pig colon. *Am. J. Physiol. Gastrointest. Liver Physiol.* **305** (12), G933-9, (2013).
17. Nicholas, S., & Spencer, N. J. Peristalsis and fecal pellet propulsion do not require nicotinic, purinergic, 5-HT₃, or NK₃ receptors in isolated guinea pig distal colon. *Am. J. Physiol. Gastrointest. Liver Physiol.* **298** (6), G952-61, (2010).
18. Hurst, N. R., Kendig, D. M., Murthy, K. S., & Grider, J. R. The short chain fatty acids, butyrate and propionate, have differential effects on the motility of the guinea pig colon. *Neurogastroenterol. Motil.* **26** (11), 1586-96, (2014).
19. Kendig, D. M., Hurst, N. R., *et al.* Activation of the umami taste receptor (T1R1/T1R3) initiates the peristaltic reflex and pellet propulsion in the distal colon. *Am. J. Physiol. Gastrointest. Liver Physiol.* **307** (11), G1100-7, (2014).
20. Gwynne, R., & Bornstein, J. Mechanisms underlying nutrient-induced segmentation in isolated guinea pig small intestine. *Am. J. Physiol. Gastrointest. Liver Physiol.* **292** (4), G1162-72, (2007).
21. Lammers, W. J. Spatial and temporal coupling between slow waves and pendular contractions. *Am. J. Physiol. Gastrointest. Liver Physiol.* **289** (5), G898-903, (2005).
22. Grider, J. R. Neurotransmitters mediating the intestinal peristaltic reflex in the mouse. *J. Pharmacol. Exp. Ther.* **307** (2), 460-7, (2003).
23. Foxx-Orenstein, A. E., & Grider, J. R. Regulation of colonic propulsion by enteric excitatory and inhibitory neurotransmitters. *Am. J. Physiol.* **271** (3 Pt 1), G433-7 (1996).
24. D'Antona, G., Hennig, G. W., Costa, M., Humphreys, C. M., & Brookes, S. J. Analysis of motor patterns in the isolated guinea-pig large intestine by spatio-temporal maps. *Neurogastroenterol. Motil.* **13** (5), 483-92, (2001).
25. Roberts, R. R., Murphy, J. F., Young, H. M., & Bornstein, J. C. Development of colonic motility in the neonatal mouse-studies using spatio-temporal maps. *Am. J. Physiol. Gastrointest. Liver Physiol.* **292** (3), G930-8, (2007).
26. Holmberg, A., Olsson, C., & Hennig, G. W. TTX-sensitive and TTX-insensitive control of spontaneous gut motility in the developing zebrafish (*Danio rerio*) larvae. *The J. Exp. Biol.* **210** (Pt 6), 1084-91, (2007).
27. Singh, R. D., Gibbons, S. J., *et al.* Ano1, a Ca²⁺-activated Cl⁻ channel, coordinates contractility in mouse intestine by Ca²⁺ transient coordination between interstitial cells of Cajal. *J. Physiol.* **592** (Pt 18), 4051-68, (2014).
28. Neal, K. B., Parry, L. J., & Bornstein, J. C. Strain-specific genetics, anatomy and function of enteric neural serotonergic pathways in inbred mice. *J. Physiol.* **587** (Pt 3), 567-86, (2009).
29. Roberts, R. R., Bornstein, J. C., Bergner, A. J., & Young, H. M. Disturbances of colonic motility in mouse models of Hirschsprung's disease. *Am. J. Physiol. Gastrointest. Liver Physiol.* **294** (4), G996-G1008, (2008).
30. Costa, M., Dodds, K. N., Wiklendt, L., Spencer, N. J., Brookes, S. J., & Dinning, P. G. Neurogenic and myogenic motor activity in the colon of the guinea pig, mouse, rabbit, and rat. *Am. J. Physiol. Gastrointest. Liver Physiol.* **305** (10), G749-59, (2013).
31. Huizinga, J. D., Martz, S., Gil, V., Wang, X.-Y. Y., Jimenez, M., & Parsons, S. Two independent networks of interstitial cells of cajal work cooperatively with the enteric nervous system to create colonic motor patterns. *Front. Neurosci.* **5**, 93, (2011).
32. Lentle, R. G., De Loubens, C., Hulls, C., Janssen, P. W., Golding, M. D., & Chambers, J. P. A comparison of the organization of longitudinal and circular contractions during pendular and segmental activity in the duodenum of the rat and guinea pig. *Neurogastroenterol. Motil.* **24** (7), 686-95, e298, (2012).
33. Bercik, P., Bouley, L., Dutoit, P., Blum, A. L., & Kucera, P. Quantitative analysis of intestinal motor patterns: spatiotemporal organization of nonneural pacemaker sites in the rat ileum. *Gastroenterol.* **119** (2), 386-94, (2000).
34. Wu, R. Y., Pasyk, M., *et al.* Spatiotemporal maps reveal regional differences in the effects on gut motility for *Lactobacillus reuteri* and *rhamnosus* strains. *Neurogastroenterol. Motil.* **25** (3), e205-14, (2013).
35. Ellis, M., Chambers, J. D., Gwynne, R. M., & Bornstein, J. C. Serotonin and cholecystokinin mediate nutrient-induced segmentation in guinea pig small intestine. *Am. J. Physiol. Gastrointest. Liver Physiol.* **304** (8), G749-61, (2013).
36. Janssen, P. W., Lentle, R. G., Asvarujanon, P., Chambers, P., Stafford, K. J., & Hemar, Y. Characterization of flow and mixing regimes within the ileum of the brushtail possum using residence time distribution analysis with simultaneous spatio-temporal mapping. *J. Physiol.* **582** (Pt 3), 1239-48, (2007).

37. Costa, M., Wiklendt, L., *et al.* An experimental method to identify neurogenic and myogenic active mechanical states of intestinal motility. *Front. Syst. Neurosci.* **7**, 7, (2013).
38. Dinning, P. G., Wiklendt, L., *et al.* Neural mechanisms of peristalsis in the isolated rabbit distal colon: a neuromechanical loop hypothesis. *Front. Neurosci.* **8**, 75, (2014).
39. Janssen, P. W., Lentle, R. G., Hulls, C., Ravindran, V., & Amerah, A. M. Spatiotemporal mapping of the motility of the isolated chicken caecum. *J. Comp. Physiol. B.* **179** (5), 593-604, (2009).
40. Janssen, P. W., Lentle, R. G., Chambers, P., Reynolds, G. W., De Loubens, C., & Hulls, C. M. Spatiotemporal organization of standing postprandial contractions in the distal ileum of the anesthetized pig. *Neurogastroenterol. Motil.* **26** (11), 1651-62, (2014).
41. Angeli, T. R., Du, P., *et al.* The bioelectrical basis and validity of gastrointestinal extracellular slow wave recordings. *J. Physiol.* **591** (Pt 18), 4567-79, (2013).
42. Kuizenga, M. H., Sia, T. C., *et al.* Neurally mediated propagating discrete clustered contractions superimposed on myogenic ripples in *ex vivo* segments of human ileum. *Am. J. Physiol. Gastrointest. Liver Physiol.* **308** (1), G1-G11, (2015).
43. Kunze, W. A., & Furness, J. B. The enteric nervous system and regulation of intestinal motility. *Annu. Rev. Physiol.* **61**, 117-42, (1999).
44. Dinning, P. G., Szczesniak, M. M., & Cook, I. J. Twenty-four hour spatiotemporal mapping of colonic propagating sequences provides pathophysiological insight into constipation. *Neurogastroenterol. Motil.* **20** (9), 1017-21, (2008).
45. Berthoud, H.-R., Hennig, G., Campbell, M., Volaufova, J., & Costa, M. Video-based spatio-temporal maps for analysis of gastric motility *in vitro*: effects of vagal stimulation in guinea-pigs. *Neurogastroenterol. Motil.* **14** (6), 677-88, (2002).