

## Video Article

# Reproductive Techniques for Ovarian Monitoring and Control in Amphibians

Natalie E. Calatayud<sup>1,2</sup>, Norin Chai<sup>3</sup>, Nicole R. Gardner<sup>2</sup>, Michelle J. Curtis<sup>2</sup>, Monica A. Stoops<sup>4</sup><sup>1</sup>Reproductive Sciences, San Diego Zoo Institute for Conservation Research<sup>2</sup>Recovery Ecology, San Diego Zoo Institute for Conservation Research<sup>3</sup>Menagerie du Jardin des Plantes, Museum National d'Histoire Naturelle<sup>4</sup>Cincinnati Zoo & Botanical Garden, Center for Conservation and Research of Endangered WildlifeCorrespondence to: Natalie E. Calatayud at [narconservation@gmail.com](mailto:narconservation@gmail.com)URL: <https://www.jove.com/video/58675>DOI: [doi:10.3791/58675](https://doi.org/10.3791/58675)

Keywords: Biology, Issue 147, Circadian, egg retention, celiotomy, exogenous hormones, ultrasound and ovariectomy.

Date Published: 5/12/2019

Citation: Calatayud, N.E., Chai, N., Gardner, N.R., Curtis, M.J., Stoops, M.A. Reproductive Techniques for Ovarian Monitoring and Control in Amphibians. *J. Vis. Exp.* (147), e58675, doi:10.3791/58675 (2019).

## Abstract

Ovarian control and monitoring in amphibians require a multi-faceted approach. There are several applications that can successfully induce reproductive behaviors and the acquisition of gametes and embryos for physiological or molecular research. Amphibians contribute to one-quarter to one-third of vertebrate research, and of interest in this context is their contribution to the scientific community's knowledge of reproductive processes and embryological development. However, most of this knowledge is derived from a small number of species. In recent times, the decimation of amphibians across the globe has required increasing intervention by conservationists. The captive recovery and assurance colonies that continue to emerge in response to the extinction risk make existing research and clinical applications invaluable to the survival and reproduction of amphibians held under human care. The success of any captive population is founded on its health and reproduction and the ability to develop viable offspring that carry forward the most diverse genetic representation of their species. For researchers and veterinarians, the ability to monitor and control ovarian development and health is, therefore, imperative. The focus of this article is to highlight the different assisted reproductive techniques that can be used to monitor and, where appropriate or necessary, control ovarian function in amphibians. Ideally, any reproductive and health issues should be reduced through proper captive husbandry, but, as with any animal, issues of health and reproductive pathologies are inevitable. Non-invasive techniques include behavioral assessments, visual inspection and palpation and morphometric measurements for the calculation of body condition indices and ultrasound. Invasive techniques include hormonal injections, blood sampling, and surgery. Ovarian control can be exercised in a number of ways depending on the application required and species of interest.

## Video Link

The video component of this article can be found at <https://www.jove.com/video/58675/>

## Introduction

Amphibians have long been recognized as important biological and medical models by a wide range of research disciplines. Data obtained by studying particular species such as *Xenopus laevis* and *X. tropicalis*, the *Leopard frog* (*Lithobates* (formerly *Rana*) *pipiens*) and the axolotl (*Ambystoma mexicanum*) have been applied to a number of other vertebrate species, including humans. The veterinary, husbandry and assisted reproductive techniques that have emerged from studying these and other amphibians provide assistance to those tasked with developing successful care, maintenance and sustainability of rarer populations in captivity<sup>1,2,3,4</sup>.

Interest is gaining for the concurrent use of in and ex situ conservation-based approaches to reverse the tide of extinction for many at risk amphibian species<sup>1,2</sup>. This article provides the methodologies presently available to monitor and control the amphibian ovarian function in model species of Anurans and Caudates. Additionally, existing techniques to address a common reproductive pathology of egg retention is presented.

As in many taxonomic groups, amphibian ovarian control involves a series of tightly synchronized interactions between the environment and physiology. Temperature and the photoperiod (known as proximate signals) are decoded by the eye and brain where they are rapidly converted into genetic, hormonal and circadian processes (ultimate signals)<sup>3,4</sup>. The methods to monitor and control ovarian function covered in this article include invasive and non-invasive techniques. Institutional Animal Care and Use Committee (IACUC) research and teaching requirements define non-invasive techniques as those that will cause minimal to no physical pain or mental distress and require no pain-relieving drugs<sup>5</sup>. Here, non-invasive techniques include visual inspection and palpation, behavioral observations, morphometric assessments and ultrasound. On the contrary, the techniques of blood collection, hormone administration and surgery (ovariectomy and removal of retained eggs) are classified as invasive since they may result in some pain or discomfort and require anesthesia or post-procedural drug therapy.

Non-invasive ovarian monitoring techniques can be easily incorporated into the daily care routine for most captive amphibians. Depending on the species, ovarian gravidity can often be determined by simple visual inspection (glass frog). In other cases, palpation may indicate whether a female is gravid. Various body condition indices (BCI) such as weight, snout urostyle length (SUL), snout-vent length (SVL) and standard mass index (SMI) are available for predicting the presence or absence of eggs<sup>4,6,7,8,9</sup>. However, care should be taken with the interpretation of results

as most do not consider age, body shape or composition (e.g., water retained versus ovarian mass or fat)<sup>6</sup>. Definitive reproductive diagnoses can be achieved via ultrasound with more in depth knowledge gained regarding egg development and staging of ovarian cycle<sup>4,7</sup>. Ultrasound also provides a means to confirm and monitor reproductive pathologies and associated physiological conditions<sup>4,8</sup>.

In addition to providing information regarding health status, blood sampling can be used to measure reproductive hormones. If hormone profiling is the final goal, it is important to avoid stress-related influences that may confound systemic steroid data. While a potentially powerful monitoring tool, there is yet to be a study demonstrating innate endocrinological responses to exogenous hormone administration in any amphibian species. Blood can safely be taken from several sites; in frogs this includes the ventral abdominal vein, lingual plexus, femoral vein and heart<sup>9,10</sup>. In Caudates, blood is collected from the ventral tail vein. The degree of invasiveness, the amount of restraint required, the need for anesthetic, the delicacy of the organ being targeted, and the size of the animal are factors to be considered when choosing a collection technique for the amphibian patient. This article will present the technique of blood collection from the facial maxillary or musculocutaneous vein of frogs as originally described by Forzan et al.<sup>9</sup>.

Ovarian control is species-specific and, as such, hormone protocols should be tested and optimized. Other than seasonality and the associated circulating hormone milieu, ovarian control may also be tightly linked to age, time spent in captivity and exposure to repeated hormone administration, for which there is little information in the literature<sup>11,12,13</sup>. The implementation of hormone therapies to elicit reproductive behaviors, gamete production, maturation and oviposition has become a widely reported approach to resolving common reproductive problems associated with captivity<sup>4,8,14,15,16</sup>. Because the mechanisms controlling reproduction in vertebrates are highly conserved, there are a number of hormones, neuropeptides and commercially available drugs used therapeutically in other taxonomic groups that can also be used reliably in a number of amphibian species (**Table 1**). Gonadotropin releasing hormone (GnRH) and Human chorionic gonadotropin (hCG) (or variations thereof, i.e., PMSG and eCG)<sup>17,18</sup>, either individually or in combination, have been used extensively in amphibian captive breeding programs including: the Southern Rocky Mountain boreal (*Anaxyrus boreas boreas*)<sup>4,19,20</sup>; the toad, Dusky Gopher frog, *Rana sevosa* (Langhorne et al., unpublished)<sup>7</sup>; the Gulf Coast Waterdog, *Necturus beyeri*<sup>20</sup>; Wyoming toad, *Anaxyrus baxteri*<sup>18</sup>; the bullfrog, *Rana catesbiana*<sup>21</sup>; the American toad, *Anaxyrus americanus*<sup>22</sup>; the grass frog, *Lymnodynaster tasmaniensis*<sup>23</sup>; the Coqui, *Eleutherodactylus coqui*<sup>24</sup>; the Xenopus, *Xenopus laevis*<sup>25</sup>; the Gunther's toadlet, *Pseudophryne guentheri*<sup>26</sup>; the Northern Leopard frog, *Lithobates pipiens*; the Argentinian Horned-frog, *Ceratophrys ornate*; the Cranwell's horned-frog, *C. cranwelli*; the American ground-frog, *Odontophrynus americanus*<sup>27</sup>; and the fire salamander (*Salamandra*)<sup>228</sup>. Steroid hormones, like progesterone (P4), are less commonly reported but have demonstrated good efficacy in eliciting ovulation and oviposition in some species of anurans<sup>16,18,29</sup>. Prostaglandins (especially Prostaglandin 2-alpha (PGF<sub>2α</sub>)) are involved in ovulation together with corticosteroids<sup>30,31,32,34</sup> and reach high levels during the ovulatory phase<sup>31</sup>.

In vitro studies, PGF<sub>2α</sub> is a potent inducer of ovulation<sup>31</sup>, while in vivo it can induce oviposition of retained eggs in *Rana muscosa*<sup>4,30,32</sup>. Pituitary extracts are also effective inducers of ovulation<sup>15,16,34</sup>, however, concerns surrounding biosecurity and the potential for disease transmission are often a deterrent for captive breeding colonies when considering this approach<sup>35</sup>.

The last section of this article details surgical procedures and provides alternate approaches to expand ovarian studies or aid with the resolution of reproductive pathologies. Ovariectomies are most commonly performed in amphibians to obtain oocytes for embryological research. However, it can also provide a remedy for retained eggs when another options fail. Although this procedure is invasive, requiring full anesthesia and incisions to expose the egg masses, it does not require euthanasia. Furthermore, after partial ovariectomy, animals can make a full recovery and continue to be reproductively active post-surgery<sup>8,36</sup>.

The protocols described below outline the invasive and non-invasive methods of ovarian control and monitoring in Anurans and Caudates. The specific species chosen to illustrate techniques in Anurans include *R. muscosa* and *X. laevis*. *Necturus maculosus*, *N. beyeri*, *N. alabamensis*, and *A. mexicanum* comprise the species used to similarly describe techniques in Caudates.

## Protocol

Salamander procedures were approved by Cincinnati Zoo & Botanical Garden (CZBG) Institutional Care and Use Committee (IACUC) protocols 11-106, 13-110, 14-133, and 15-138. All frog and toad procedures were approved by the San Diego Zoo Global (SDZG), Institutional Care and Use Committee (IACUC) protocols: 15-001, 16-005 and 18-003.

The care and treatment of animals was approved by the Ethical Committee of the National Museum of Natural History (Paris) (Museum National d'Histoire Naturelle-Ménagerie du Jardin des Plantes (MNHN)), in accordance with the Institutional and National Guidelines (Commission de Génie Génétique, Direction Départementale des Services Vétérinaires, European Union Directive 2010/63/EU, agreement decision No. C75-05-01-2 for the European Convention for vertebrate animals used for experimental and other scientific purposes. All protocols used in this study were approved under the reference number 68-037.

## 1. Non-invasive ovarian monitoring techniques

1. Visual inspection and palpation
  1. Hold the female Anuran in one of the three ways described below.
    1. Secure the frog or toad's legs with the ring and little finger, supporting the dorsal side (abdomen) of the frog's body with the index and middle finger and the ventral side with the thumb (**Figure 1A**).
    2. Hold the frog or toad in the dominant hand with a thumb on its abdomen and the rest of the fingers securing the back of the animal. Using the non-dominant hand to palpate the animal's abdomen, feel if there is subdermal bumpiness (**Figure 1B**).
    3. Rest the frog or toad's abdomen on the palm of the hand, front arms draped over the index finger and a thumb on its upper back.
  2. Since Caudates are fully aquatic in nature, perform visual inspection by one of two methods described below.
    1. Move animal to a separate 4 L container containing tank water. Hold the container (lid secured) up and shine flashlight on the underside to visualize the presence/absence of eggs.

2. Anesthetize in MS222 (0.5 g/L; Tricaine methanesulfonate, buffered with 0.5 M NaHCO<sub>3</sub>). Following induction, rotate animal onto its back and examine abdomen.
2. Morphometric assessments
    1. Anurans
 

NOTE: Anesthesia is not required.

      1. Using calipers, measure the animal from the tip of the mouth, along the center of the body to the tip of the tail to obtain SUL and SVL (**Figure 2A,B**).
      2. Tare a plastic container on a digital precision scale. Place the animal in a tared container and weigh (**Figure 2C**).
      3. For larger animals, like bullfrogs, or when obtaining weights in the field, use a hanging scale (**Figure 2D**).
      4. As in many anuran species, distinguish *R. muscosa* adult females from males by their larger size and the lack of nuptial (thumb) pads on the hands (**Figure 3**).
      5. Calculate the body condition, as a basic assessment of overall health by the following formula:  
Fulton's index:  $K = \text{mass} \div \text{length}^3$   
NOTE: Fulton's Index uses a dimensional balance of volume related to mass and length where <sup>3</sup> is the scaling exponent that relates mass and length isometrically.
    2. Caudates
      1. Tare scale with an empty bag before placing the non-anesthetized animal inside. Take care to not introduce excess water (**Figure 2D**) and act quickly as animals secrete mucus as a stress response to being restrained.
      2. Obtain adult measures by immobilizing individuals in a straight position at the bottom of a re-sealable plastic bag or in a separate plastic container that can accommodate expanded calipers.
      3. Measure the body length with calipers (**Figure 2E**).
      4. Measure caudate from tip of snout to tip of tail (SVL) to monitor growth.
  3. Behavioral observations
    1. Physically observe animals in real-time or use a video camera to record behavior.
    2. Record observations of animals categorize behaviors and construct an ethogram (**Figure 4**).
    3. Classify reproductive behaviors  
NOTE: **Figure 4** exemplifies one type of reproductive behavior observed in anurans.
  4. Ultrasound
 

NOTE: The ultrasound transducer of choice, in this instance, 7.5 MHz linear or a multi-frequency (10-6 MHz) micro-convex, is recommend for *Necturus* and a 10 MHz probe and water soluble, salt-free gel for *R. muscosa*. Performing ultrasound on salamanders may require anesthesia (see section 1.5 for instructions).

    1. Anurans
      1. Perform ultrasound on *R. muscosa* using two people (**Figure 5A**).
      2. First person: Hold the animal with the dominant hand and apply the water soluble, salt free gel to the animal's abdomen.
      3. Second person (ultra-sonographer): Take the 10 MHz probe in the dominant hand and apply it to the abdomen making sure to make good contact between the probe and gel.
      4. Slide inwards from just below the arm pit towards the center of the animal's abdominal midline to visualize the whole ovary.
      5. Ultra-sonographer: Use non-dominant hand to freeze frame and capture the desired images on the ultrasound.
      6. Categorize the stage of the ovarian cycle by the grading system established for the genus<sup>4</sup> (**Table 2, Figure 5B-F**).
      7. Rinse any gel off animal at the end of the procedure.
    2. Caudates
      1. Transfer non-anesthetized *Necturus* to 4 L rectangular container filled with 2 L of tank water.
      2. Minimize animal movement by turning the room lights off and/or cup one hand over the head of the animal.
      3. Position the transducer at a distance of 1-2 cm from body wall.
      4. Locate the heart at the ventral midline level to the forelimbs and then move transducer distally and examine the ovarian tissue<sup>7</sup>.
      5. Categorize females according to grading system established for the genus<sup>4</sup> (**Figure 6A,B,C**).
      6. Obtain accurate measures of eggs at mid-to late-gravid stage by capturing images when the animal's body is at an angle to the transducer (i.e., not linear, but slight arc; **Figure 6B**). Otherwise, overlapping follicles make it difficult to differentiate individual egg size.
  5. Anesthetic induction and recovery
    1. Anurans
      1. Anesthetize in MS222 (0.5 g/L; Tricaine methanesulfonate buffered (0.5 M NaHCO<sub>3</sub>) as previously described.
      2. Use the righting reflex as a primary indicator of the degree to which the animal has become anesthetized. Complete loss of reflex demonstrates a state of deep anesthesia.
      3. Remove the animal from the water-bath-based anesthesia (MS-222) once the righting reflex is lost.
      4. Place the animal on a wet (with anesthetic-free de-chlorinated water) towel.
      5. Make sure to keep the animal moist during the entire surgical procedure.
      6. Intubate small amphibians with red rubber catheters, uncuffed tubes or classical cuffed endotracheal tubes without inflating the cuff.
      7. Provide a low flow of oxygen (0.5-0.75 L/min) with 0.5-1% isoflurane.
      8. Stop the isoflurane after the procedure but keep the flow of oxygen for 1 minute.
      9. Extubate the animal and rinse the animal thoroughly with anesthetic-free dechlorinated water for 2 minutes.

10. Put the animal in a shallow amount of de-chlorinated water or on a wet towel.
11. Evaluate the animal's recovery by gently pulling on a hind limb to elongate. Any responding contraction of the limb indicates withdrawal reflex.
12. Monitor other indicators of recovery such as gular respirations (throat movement) and the righting reflex.
13. Consider the amphibian recovered when all of the reflexes have returned, and heart and respiration rates have returned to pre-anesthetic values.

## 2. Caudates

1. Anesthetize *Necturus* and *Ambystoma* in MS222 (0.5 g/L of Tricaine methanesulfonate, buffered with 0.5 M NaHCO<sub>3</sub>, (MS222) in a 4 L rectangular tank.
2. Place an air stone (1 inch) and air pump into the tank and turn it on to a constant flow to provide adequate oxygenation.
3. When the limb function and the righting reflex are lost, remove the animal from the water-bath-based anesthesia (MS-222) and put the animal on a wet (with anesthetic-free de-chlorinated water) towel.
4. Maintain skin and gill moisture with a squeeze bottle of tank water.
5. To recover the animal, carefully place it ventral side down in a 4 L plastic container filled with 2 L of tank water with an air stone.  
NOTE: Recovery starts with gill flashing, followed by the ability to move its tail and propel forward and finally functional movement of limbs.
6. Return the animal to its original housing tank and monitor closely over the next 24 h.  
NOTE: Other methods of anesthesia for amphibians exist and these are described in Wright and Whitaker<sup>8</sup>.

## 2. Invasive ovarian monitor and control techniques

NOTE: This procedure has been adapted from Forzán et al.<sup>10</sup>.

1. Hold the frog in the dominant hand, and dab dry the venipuncture side of the frog's face with a sterile wipe or gauze.
2. Dry the face to avoid the blood from dispersing across the skin too much.
3. Insert the needle (26 G 1/2" and 27 G 1/2"), with the bevel facing upwards, through the skin where the raised skin around the eye and the upper jaw ridge meet to form the point of a triangle (yellow outline) (**Figure 7A**) accessing the *vena facialis* near the *vena orbitalis* posterior.
4. Puncture the facial vein below the right eye and above the upper jaw ridge, starting between 1-2 mm back from the midline of the eye (**Figure 7A**).  
NOTE: For smaller frogs (under 20 g), move the insertion point closer to a position directly below the midline of the eye.
5. Angle the microhematocrit tube downward to enable gravity to help blood flow into the tube. Blood should flow immediately after puncture (**Figure 7B,C**).
6. At the first sign of blood flow, place the tip of microhematocrit tube at the puncture site and collect 1-2 full microhematocrit tubes of blood and place tubes into suitable receptacles for collection (**Figure 7B,C**).
7. If blood does not flow readily, or the volume is very low, shift the insertion of the needle slightly or insert the needle into the other side of the face.
8. Stop bleeding by pressing gauze firmly to the puncture site for at least 20 s.
9. Leave frog out of water for 10 minutes to confirm puncture site does not reopen.
10. Use a new needle and new microhematocrit tubes for each frog sampled.

## 3. Hormone induction

### 1. Hormone preparation

1. Prepare hormone injections immediately prior to use to ensure maximum effect.
2. Select a hormone from the selection listed in **Table 1**.
3. Determine the concentration of the hormone to be injected using a  $\mu\text{L}$  or  $\text{mL/g}$  of body weight<sup>16</sup>.
4. Dilute the hormone in one of the following: water, phosphate buffered saline (PBS), saline amphibian Ringer's solution (SARS) or saline.
5. Do not exceed an injection volume of 200  $\mu\text{L}$  for frogs weighing 30-70 g and 300  $\mu\text{L}$  for frogs weighing 80-110 g (personal observation)<sup>16</sup>.
6. For correct holding of an animal during hormone administration of any animal ranging from 10-100 g, use any of the appropriate methods for holding described in section 1.1.

### 2. Anurans

1. Calculate the concentration required per individual using a gram per body weight calculation (g/body weight).
2. Just prior to administration, reconstitute in a sterile diluent of choice.
3. Ensure no bubbles are left in the syringe before injection.
4. Hold the animal securely in the non-dominant hand and administer the injection with dominant hand.
5. Administer injection according to hormone specifications. The most common injections in anurans are sub-cutaneous, intra peritoneal or intra muscular (**Figure 8**).
6. Administer IP injections in the lower part of the abdomen or in the lower section of the dorsal side of the body near the back leg (**Figure 9**).
7. Administer intra-muscular injections preferably into the hind legs.

### 3. Caudates (*Necturus*)

1. Reconstitute the hormone of choice in sterile water according to the gram per body weight method described above.

2. In the case of *Necturus*, use doses of 1.7-2.3 µg GnRH/g body weight.
3. Remove *Necturus* from anesthetic chamber and place on a 45° surface covered with surgical drape.
4. Position the animal with head pointing down.
5. Approach posterior quadrant of the abdomen (caudal of rear leg) at a 15-20° angle. Be careful not to introduce air into the syringe.
6. Inject (IP) using an insulin syringe and 27-30 G needle.
7. Inject the hormone using an insulin syringe and 27-30 G needle.

## 4. Surgery

1. General surgical preparation and procedure
  1. To maintain aseptic procedures, use clear sterile plastic drapes to isolate surgical site. Reduce evaporation by keeping the surrounding skin moist.
  2. Moisten any materials that will contact the animal's skin with sterile water. Make skin incision with a number 15 or number 11 scalpel blade.  
NOTE: A combination of cold steel, radiosurgery or diode laser. Hemostasis in mild hemorrhagic procedure may be achieved by electrocauter or diode laser.
  3. Use cotton-tipped spears or applicators to allow the application of localized pressure to small vessels keeping track of blood loss.
  4. Use cotton-tipped spears or applicators to manage small confined spaces instead standard gauze squares.
  5. Use micro-instruments, like ophthalmologic instruments, with fine, small tips, when performing surgery on animals' weighing less than 1 kg.
  6. Use plastic, self-retaining retractors (e.g., Lone Star retractor) to fit different sizes of incisions.
  7. Use eyelid retractors for retracting coelomic incisions.
  8. Use magnification instrumentation where necessary for performing surgery on smaller patients.  
NOTE: Analgesia is required with any surgical procedure in amphibians. Failure to administer adequate analgesia during surgery has been associated with delayed return of normal functions. Moreover, analgesia potentiates the effects of anesthetic drugs (Table 3)<sup>34</sup>.
2. Anurans
  1. Once *X. laevis* has been anesthetized as described in step 1.5.1, position the animal in dorsal recumbency (Figure 10A,C).
  2. Prepare the surgical field aseptically by wiping moist sterile gauze with dilute povidone-iodine solution (1/10) on the site for 10-15 s or 0.75% chlorhexidine solution on the surgical site for at least 10 min before the surgery<sup>35</sup>.
  3. Make a 3 mm paramedian skin incision in the mid coelom (between the shoulders and the cloaca) with one bold stroke leaving a clean incision using a no. 15 or no. 11 scalpel.  
NOTE: One may use a diode laser also for skin incisions.
  4. Elevate the abdominal membrane, make an incision and dissect carefully using a no. 15 or no. 11 scalpel. (Figure 10B,D).
  5. Retract the coelomic incisions with eyelid retractors (or any appropriate equipment).
  6. Excise a portion of egg mass without ligating any blood vessels.
  7. For complete ovariectomy, cauterize surrounding blood vessels by electrocautery or laser diode (Figure 11).
  8. Using monofilament suture, close celiotomy incision with an interrupted, everting suture pattern.
3. Caudates
  1. Once *A. mexicanum* has been anesthetized, place it in the right lateral recumbency, with the left pelvic limb simply placed against the tail base.
  2. Prepare the surgical field aseptically by placing moist sterile gauze with dilute povidone-iodine solution (1:10) on the site for 10-15 s. Alternatively, use sterile gauze soaked in 0.75% chlorhexidine solution and place on the surgical site for at least 10 min before surgery (Figure 12A)<sup>36, 37</sup>.
  3. Draw a line between the shoulder and the hind limbs to divide the body into three equal parts (Figure 12B).
  4. Make the incision site between the second and third parts.
  5. Grasp the underlying muscle and elevate away from the coelomic viscera.
  6. Gently force small hemostats through the coelomic musculature and into the coelomic cavity.
  7. Retract the coelomic incisions with eyelid retractors (or any appropriate material) (Figure 12C).
  8. For complete ovariectomy, cauterize surrounding blood vessels by electrocautery or laser diode (Figure 12D).
  9. Using monofilament suture, close celiotomy incision with an interrupted, everting suture pattern.

## Representative Results

### Morphometrics and reproduction

Visualization of female reproductive status in amphibians varies depending on the species. The most effective method is ultrasound; however, some species may show varying degrees of transparency of their skin (Figure 13A,B,C). Visual inspection can often clearly illustrate the differences between a gravid and non-gravid female when the skin is semi-translucent as observed in *N. alabamensis* and *N. maculosus* (Figure 13A,B); or translucent as illustrated by the Glass frog (Figure 13C). The dark spotted skin coloration on the abdomen of *N. beyeri* prohibits this assessment to be made. In *R. muscosa*, the skin is not translucent but noticeable differences can be detected between females that are gravid compared to those that have recently oviposited because the skin is flaccid, and the animal looks thinner (yellow line) compared to a female that is gravid (blue line) (Figure 13D). With experience the handler can familiarize themselves with the difference between a large female and a gravid one but confirmation of gravid stage will require ultrasound. Body mass indices in amphibians can be calculated using a number of



formulas but their application as a predictive tool for reproduction is debatable. In the case on *R. muscosa*, correlation between Fulton's index, health and reproductive status remains unclear.

### Reproductive behavior and ultrasound

Our results show how to characterize reproductive behaviors in *R. muscosa* for the prediction of oviposition (**Figure 4**). Several stages lasting from a few hours to several weeks include, courting where a male actively chases a female (**Figure 4A**), the male mounts and firmly clasps onto the female's back, termed amplexus (**Figure 4B**). Once amplexed, the pair can remain in amplexus for 1 – 5 weeks and the pair will display other behaviors in addition to amplexus. Amplexus is a very active behavior that includes the male squeezing the female in a soft pumping manner (**Figure 4C**); the female moving around and beginning to display hand-stand behaviors intermittently (**Figure 4D,E**); and closer to the time of oviposition, the female, in a hand-stand, will lean up against surfaces that she can stick eggs onto while the male pumps her abdomen vigorously (in this instance it is possible to also observe the female rubbing her abdomen downwards from under her arm pits towards the cloaca. This may be a mechanical way with which to push eggs down the oviducts) (**Figure 4F,G**).

This study illustrates how ultrasound can provide information with which to ascertain reproductive status in female *R. muscosa* and *Necturus*. Four stages of development are represented in *R. muscosa* (**Figure 5C,D,E,F**) and are similarly characterized in *Necturus*<sup>4</sup> (**Figure 6A,B,C**). In addition, residual eggs can fail to be expelled leading to egg retention (**Figure 5G, Figure 15A,B**). Stage 1 shows an ovary directly after oviposition where follicles are hard to visualize (**Figure 5C**). Stage 2 is represented by the appearance of echogenic dots (white flecks) dispersed throughout the ovary (**Figure 5D**). Stage 2 and 3 are represented by larger, rounded echogenic dots with dark centers that represent yoked medium to large follicles (**Figure 5E,F**). From 2013-2017, captive female *Necturus* were examined by ultrasonography on a monthly basis. During each exam individuals were assigned a grade score according to the reproductive criteria established for the genus (**Table 2**). The percentage of females developing new eggs each year averaged  $88.2 \pm 3.01\%$  (**Table 5**). While egg development was high, oviposition was not ensured (**Figure 16**). A majority of females that underwent oviposition deposited the full complement of eggs, while some individuals deposited only a fraction of the eggs that developed. Those *R. muscosa* and *Necturus* females with retained eggs concomitant with fluid gain in the body cavity were outwardly visually enlarged with red patches on the skin consistent with burst blood vessels (**Figure 14A,B**). The degree of fluid retention could be further assessed via ultrasound (**Figure 15B**). In both species, retained eggs underwent atresia or took upon a more echogenic appearance (**Figure 14C,D, Figure 15A**).

### Hormone administration

Depending on the depth of the type of injection the angle and depth of the needle will vary. For most injections the depth of the needle need not be more than 1-2 mm deep when working with species such as *R. muscosa* but will vary in the angle of penetration. Prostaglandin injections required an intra-muscular (im) needle insertion angled at 90°, into the hind leg of *R. muscosa* while intra-peritoneal (ip) injections, with a similar depth to intra-muscular injections, were administered in the area of the coelomic cavity at a 45° (**Figure 10**). Administration of Amphiplex had no significant effect in increasing the number of eggs deposited by hormone-treated females compared to controls ( $P = 0.547$ ), nor were there any differences in the number of embryos that cleaved ( $P = 0.673$ ) or survived to tadpole ( $P = 0.629$ ) (**Table 4**). Generally, the percentage of females ovipositing decreased from 80% in 2011 to 28% in 2014. The number of females ovipositing in 2015 was significantly higher than 2013 ( $P = 0.0002$ ), 2013 ( $P = 0.0001$ ) and 2014 ( $P = 0.0026$ ) but not 2011 ( $P = 0.0885$ ), reaffirming the idea that females of this species may not breed annually and that hormonal protocols require refinement. For *R. muscosa* females with signs of egg retention, intra-muscular injections of PGF<sub>2α</sub> had a 60% success rate in inducing expulsion of degenerating eggs. However, in 1 of the 5 females injected, PGF<sub>2α</sub> was not sufficient to cause complete expulsion and some eggs remained inside the female till the following breeding season. Seventeen *Necturus* females received LHRH/(GnRH) and 13 received a sham injection of sterile water to serve as a control (**Table 5**). In total, seven female *Necturus* ( $n = 4$  *alabamensis*,  $n = 2$  *beyeri*,  $n = 1$  *maculosus*) went on to oviposit eleven full clutches that were attributed to both GnRH treated ( $n = 6$ ) and control ( $n = 5$ ) individuals. Three females ( $n = 2$  *beyeri*,  $n = 1$  *maculosus*) oviposited five partial clutches (**Figure 13**). This phenomenon did not appear to be associated with exogenous hormone treatment as three control females similarly deposited partial clutches (**Table 5**). Oviposition occurred over a 37-day (3/31-5/7) timeframe over the course of five years (**Table 5**). There was no difference ( $P = 0.194$ ) in oviposition rates between LHRH/GnRH treated ( $41 \pm 13.08\%$ , range 17-67%) and control ( $66.75 \pm 11.79\%$ , range 50-100%) females. LHRH/GnRH treated females deposited eggs an average of  $7.44 \pm 1.41$  (range 3-13) days post-injection. Given the fully aquatic nature of the species and inability to manually restrain without anesthesia it was necessary to ensure an appropriate level of sedation before performing IP hormone injections (see section 3.2 for instructions on anesthesia).

### Blood collection, anesthesia and surgery

The blood sampling technique in this article was taken from Forzan et al. 2013<sup>10</sup> and has proven an effective way to collect blood from *R. muscosa* with minimal invasiveness and stress. Using microhematocrit tubes, approximately 35-45µl of plasma or serum can be collected per 70 µL of whole blood (**Figure 7**). Maximum collection volume in *R. muscosa* was 1 full microhematocrit tube per 10 g of frog, up to 4 tubes per frog for frogs 40 g and larger. This was a conservative collection volume of 0.7 mL per 100 g, 70% of the maximum recommendation of 1.0 mL per 100 g (adapted from Allender and Fry, 2008)<sup>13</sup>.

Anesthesia and surgery in amphibians are rarely reported but it is important to note that doses and efficacy will vary in a species-specific manner. In *Bombina orientalis* for instance, MS222 has a very low effect, even with high doses (1 g/L) whereas in Boreal toads, *Anaxyrus boreas boreas*, 1 g/L is fast (matter of minutes) and long lasting (3+ h) (Calatayud, personal observation). In *R. muscosa*, anesthesia requires doses reported for *A. boreas boreas* and has similar effect and recovery times. Fasting amphibians prior to anesthesia is not usually required as their larynx remains tightly closed even under general anesthesia. However, if deemed necessary, especially if the anesthetic procedure is to include celomic surgery, animals can be fasted 24 h prior to anesthesia.

During surgery, the righting reflex is the primary indicator that the animal has become anesthetized. The righting reflex is the ability and degree of ease with which an animal can return to an upright position after being placed on its back. Loss of the reflex suggests a light stage of anesthesia. A surgical plane is indicated by loss of the withdrawal reflex which includes lightly pulling on the limb to straighten it and the animal no-longer being capable of retracting it<sup>1</sup>. Reproductive surgery has no overwhelming obstacles and amphibian patients predominantly heal well tolerating blood loss more than higher vertebrates. Surgery should proceed quickly, lasting approximately 15 minutes from beginning to end. Steps

should be timed approximately as follows: <1 minute for the initial incision and <2 minute for celiotomy and retractor insertion, < 2-3 minutes for isolation per ovary and <1 minute for vessel suture or cauterization and skin suture < 4 minutes. The total recovery time after surgery with MS222 protocols are approximately 45 minutes but this can be species-specific. In *A. boreas boreas* and *R. muscosa* recovery times can be longer, up to 1 – 2 h. When performing surgery, care must be taken to avoid puncturing the lungs, the gastrointestinal tract or a distended bladder, and not to damage the macroscopic glands, lymph hearts, and blood vessels, especially the mid-ventral vein. Depending on season, the presence of large fat bodies can make visualization of other organs difficult. Once visibly awake, an animal's responses to limb stimulation, such as resistance to a gentle stretching of a back limb or blinking when the area around the eye is stimulated (personal observation), are classified as withdrawal responses. The righting reflex along with other recovery indicators including, the withdrawal reflexes and gular movements, are important indicators of recovery.

Common name	Species	Hormone	Procedure	Priming compound	Administration				Doses	Reference
					Priming dose reported	Number of priming doses	Timing (hr prior to ovulatory dose)	Compound(s) administered for final ovulatory/oviposition		
Puerto Rican Crested toad	<i>Pelitophryne lemur</i>	GnRH & hCG	IP	hCG	1.5 IU/g	2	hCG - 48	GnRH; hCG; GnRHa + hCG	0.2 µg; 4 IU; 0.5 µg + 4 IU	Calatayud et al. unpublished
Mountain yellow-legged frog	<i>Rana muscosa</i>	Amphiplex, Lut	IP	GnRHa (des-Gly10, D- Ala6, Pro-NHEt9-GnRH)	0.4 µg/g	1	24	GnRH + MET	1 x 0.4 µg/g + 10 µg/g	Calatayud et al., 2018
		PGF <sub>2</sub> α	IM	PGF <sub>2</sub> α	5 ng/g	1	48	PGF <sub>2</sub> α	5 ng/g	
Southern Rocky Mountain boreal toad	<i>Anaxyrus boreas boreas</i>	hCG, GnRH	IP	hCG	3.7 IU/g	2	96, 24	hCG + GnRHa	13.5 IU/g + 0.4 µg/g	Calatayud et al., 2015
Northern Cricket frog	<i>Acris crepitans</i>	Amphiplex	added to water (10 mL)	None	None	0	na	GnRH + MET	0.17 µg + 0.42 µg / µl	Snyder et al., 2012
Northern Leopard frog	<i>Lithobates pipiens</i>	Amphiplex	IP	None	None	0	24	GnRH + MET	1 x 0.4 µg/g + 10 µg/g	Trudeau et al., 2010
Argentine Horned frog	<i>Ceratophrys ornata</i>	Amphiplex	IP	None	None	0	24	GnRH + MET	1 x 0.4 µg/g + 10 µg/g	
Cranwell's horned frog	<i>Ceratophrys cranwelli</i>	Amphiplex	IP	None	None	0	24	GnRH + MET	1 x 0.4 µg/g + 10 µg/g	
American ground frog	<i>Odontophrynus americanus</i>	Amphiplex	IP	None	None	0	24	GnRH + MET	1 x 0.4 µg/g + 10 µg/g	
Dusky Gopher frog	<i>Rana sevososa</i>	hCG, GnRH	IP	hCG	3.7 IU/g	2	96, 24	GnRH + hCG	1 x 0.4 µg/g + 13.5 IU/g	Graham et al., 2018
Common coqui	<i>Eleutherodactylus coqui</i>	Fish, avian, mammalian & GnRH (D-Ala, des-Gly, eth LHRH), hCG	SC	mLHRH; aLHR; fLHRH; GnRHa; hCG	None	0	na	mLHRH; aLHR; fLHRH; GnRHa; hCG	7µg, 33µg; 28µg; 7µg, 20µg; 5, 10, 15, 20 µg; 165 IU	Michael et al 2004
Gunther's toadlet	<i>Pseudophryne guentheri</i>	GnRH		GnRHa	0.4 µg/g	1	26	GnRHa with or without prime	0.4 µg/g	Silla 2010
Corroboree frog	<i>Pseudophryne corroboree</i>	Lucrin	SC	Lucrin	1 µg	1	26	Lucrin	5 µg	Byrne & Silla, 2010
Northern Corroboree frog	<i>Pseudophryne pengilleyi</i>	GnRHa GnRH (D-Ala, des-Gly, eth LHRH)	TA	None	None	0	na	GnRHa	0.5 -2.0 µg/g	Silla et al., 2017
Gulf coast waterdog	<i>Necturus beyeri</i>	[des-Gly10, D-Ala6]-LHRH-RH ethylamide acetate salt hydrate	IP	None	None	0	na	LHRH	100 µg / 500 µL	Stoops et al., 2014
Southern bell frog / growling grass frog	<i>Litoria raniformis</i>	des-Gly10, D-Ala6-[LHRH]	SC	None	None	0	na	des-Gly10, D-Ala6-[LHRH]	50 µg	Mann et al., 2010
Fowler's toad	<i>Anaxyrus fowleri</i>	GnRH, hCG, P4	IP	hCG	3.7 IU/g					Browne et al., 2006
Axolotl (Mexican salamander)	<i>Ambystoma mexicanum</i>	Follicle-stimulating hormones	IM	None	None	0	na	FSH	400IU	Trottier and Armstrong, 1974
African clawed frog	<i>Xenopus laevis</i>	hCG & P4	added water; IP	PMSG, hCG						Marcec , 2016
Tiger salamander	<i>Ambystoma tigrinum</i>	hCG, LH								
Wyoming toad	<i>Anaxyrus baxteri</i>	hCG, GnRHa, P4	IP	hCG + GnRHa	100 IU + 0.8 µg	1	72	hCG + GnRHa	100 IU + 0.8 µg	Browne et al., 2006
Northern Leopard frog	<i>Lithobates pipiens</i>	Pituitary extract (PE), P4, testosterone (T), corticosterone [C], Amphiplex, domperidone (D)	SC, IP	None	None	0	na	PE, PE+T, PE +P4, PE+C; Amphiplex, GnRH + D	~100 IU (LHRH) in 1 mL; PE +0.002µg/µL; PE +0.01mg/50mL; PE +0.1mg/50mL; 0.4 µg/g + 10 µg/g; 0.4 µg/g + D	Wright, 1961; Fort, 2000; Trudeau et al., 2013
Ground frog	<i>Lymnodynastes tasmaniensis</i>	Pituitary extracts, hCG, GnRHa, PZ	IP	GnRHa	0.9-1.2µg/g + PZ 10 µg/g	1	20	PE; PE + hCG; GnRH + PZ	PE vol; PE vol + 100 IU hCG; GnRH	Clulow et al., 2018



									(0.9-1.2µg/g) + PZ (10µg/g)	
Green and Golden Bell frog	<i>Litoia aurea</i>	GnRH	IP	GnRHa	10 µg	1	72	GnRHa + hCG	20 µg + 300 IU	Clulow et al., 2018
Great Barred frog	<i>Mixophyes fasciolatus</i>	hCG & PMSG	SC	PMSG, hCG	50 IU & 25 IU; 1x100 IU	2; 2	PMSG-144 & 96; hCG-24	hCG	100IU	Clulow et al., 2012
For more hormone protocols and species see Wright and Whitaker, 2001										

**Table 1: Amphibian species and some of the exogenous hormones tested on them as reported in the literature.** Human chorionic gonadotropin (hCG); Gonadotropin releasing-hormone (GnRH); Lutenizing hormone-releasing hormone (LHRH); the letters m, a and f represent 'mammal', 'avian' and 'fish'; pregnant mare serum gonadotropin (PMSG); progesterone (P4); Follicle-stimulating hormone FSH); pituitary extract (PE); testosterone (T); corticosterone (C). Dopamine antagonists listed include: domperidone (D); Pimozide (P); metoclopramide (MET). Amphiplex is name given to a compound made up of GnRH and Metoclopramide<sup>27</sup>. Lucrin is a commercially available GnRH agonist with the active ingredient being Leuprorelin acetate.<sup>4,7,17,18,19,20,26,27,38,39,40,41,42,43,44,45</sup>

Grade	Reproductive status	Description
0	Non-gravid	No eggs visible.
1	Early gravid	Eggs visible (1-2mm in size) no distinct echogenic line associated with egg.
2	Mid gravid	Eggs 2-3mm in size, distinct echogenic line(s) associated with each egg.
3	Late gravid	Eggs 4-5mm in size, echogenic lines still visible, marked increase in anechoic appearance of egg.
4	Retained eggs	Varying degrees of echogenic material present in internal egg structure, take on amorphic shape. Some may become very echogenic and associated with fluid retention in body cavity.

**Table 2: Grading system used to score the reproductive state of captive female *Necturus* and *Rana muscosa* by ultrasonography.**

Drug	Dosage and Route	Comments - reference
Buprenorphin	50 mg/Kg (intracelomic)	Experimental study in an eastern red-spotted newt ( <i>Notophthalmus viridescens</i> ). Analgesia should be given before surgery. (Koeller, 2009)
Butorphanol	1 – 10 mg/Kg (IM or intracelomic)	There are various specific respons. It is advised to start at 1 mg/kg.
Butorphanol	0.5 mg/L (bath)	Experimental study in an eastern red-spotted newt ( <i>Notophthalmus viridescens</i> ). (Koeller, 2009)
Fentanyl	1 mg/kg	Analgesia > 4 h, antagonized by naltrexone (Stevens, 1997)
Meloxicam	0.1 to 0.2 mg/kg (IM)	(Minter, 2011)

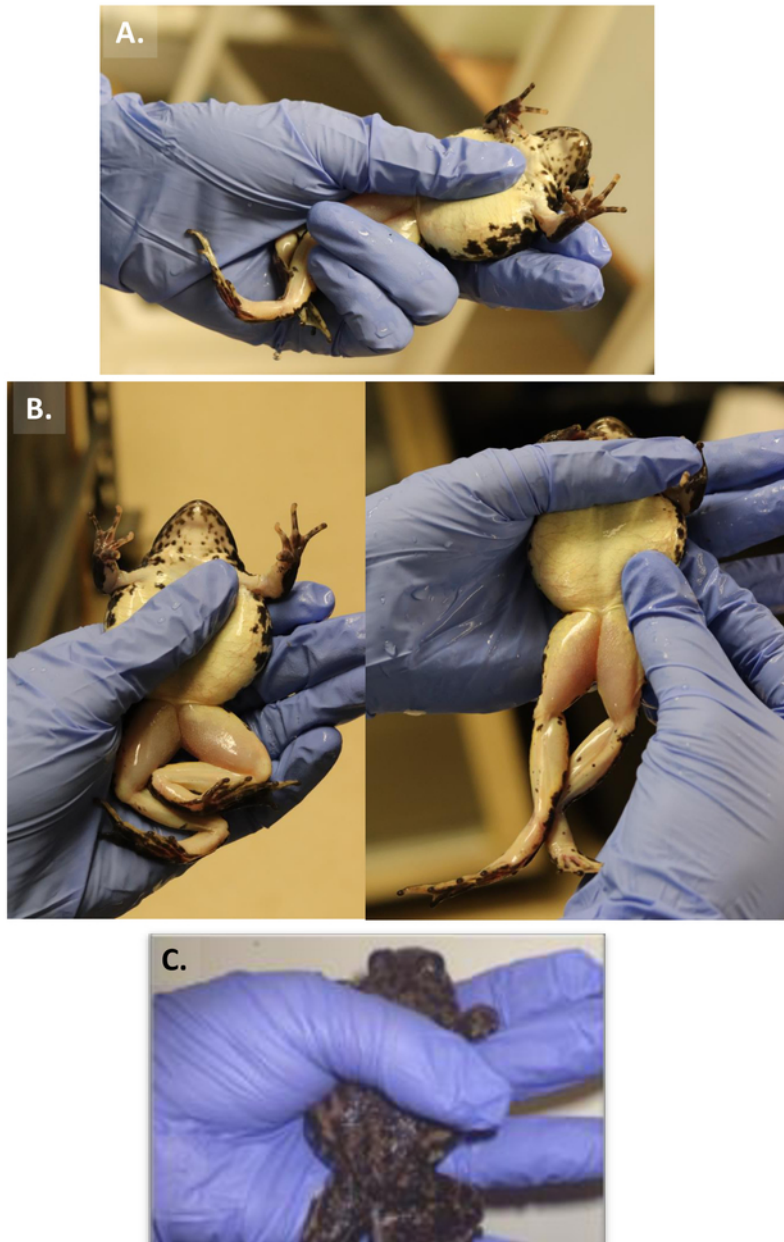
**Table 3: Protocols for analgesia in amphibians.**

	<i>Rana muscosa</i>	
Year	2014	2015
No. ♀	18	18
Egg Development	61%	94%
Control ♀	4	6
Amphiplex ♀	4	7
Average day post Amphiplex to oviposit	10.5	10.9
Oviposition Rate (Amphiplex)	22.20%	33.33%
Oviposition Rate (Control)	22.20%	38.88%


**Table 4: A comparison of reproductive parameters between amphiplex-treated compared to control captive female *Rana muscosa* in 2014 and 2015.**

<i>Necturus</i> sp.					
Year	1	2	3	4	5
No. ♀	6*	7	7*	7*	7*
Egg Development	83%	100%	86%	86%	86%
LHRH ♀	3	5	3	6	0
Control ♀	2	2	3	0	6
Day post-LHRH to Oviposit	5	7	5.5 (range 3 - 8)	13	n/a
Oviposition Rate (LHRH)	60%	20%	67%	17%	n/a
Oviposition Rate (Control)	50%	50%	100%	n/a	67%
* n=1 ♀ no egg development					

**Table 5: A comparison of reproductive parameters between LHRH(GnRH)-treated and control (sterile water) captive female *Necturus* from three species over a 5-year period of time (2012-2017).**



**Figure 1: Three methods of holding a frog.** (A) Procedure 1. (B) Procedure 2. (C) Procedure 3. [Please click here to view a larger version of this figure.](#)



**Figure 2: Morphometric assessments.** (A, B) SVL/SUL (C, D). weight, in *R. muscosa* and *D. Necturus*. (E). Size measurement with calipers. [Please click here to view a larger version of this figure.](#)

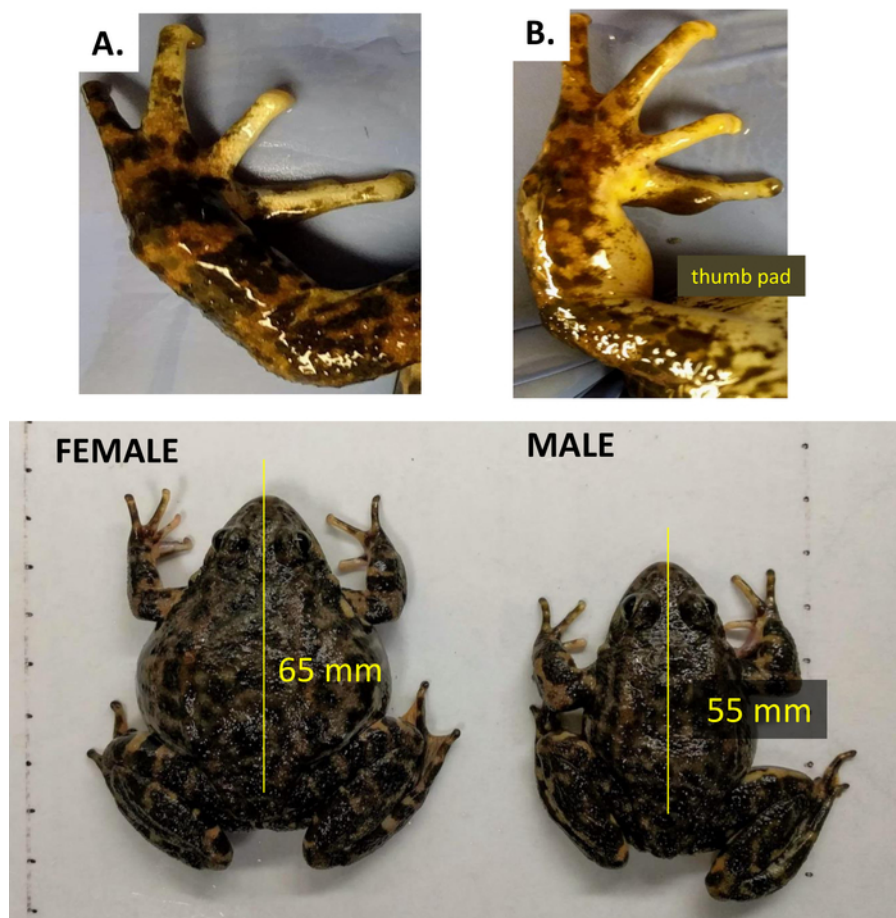


Figure 3: Sexual dimorphism is distinguished by nuptial thumb pads on adult *R. muscosa* males compared to females. (A) Female (B) Male. The lower panel shows the length of male vs female. [Please click here to view a larger version of this figure.](#)





0 = not amplexed/attempting amplexus 1 = amplexed

2 = amplexed with male squeezing

3 = amplexed female abdomen rub  
4 = amplexed female in hand-stand


6 = amplexed female w contractions



5 = amplexed female

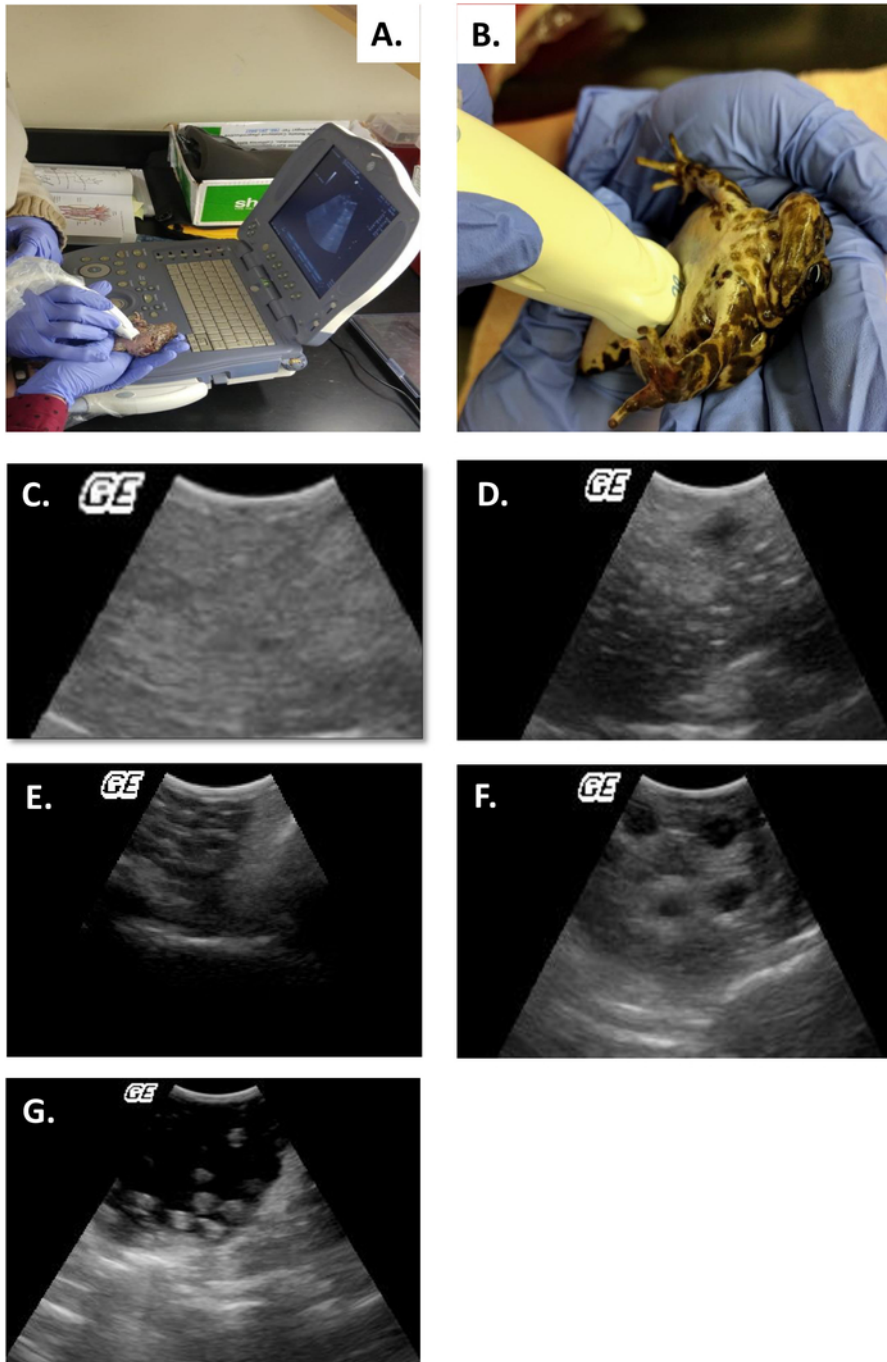


7 = Oviposition

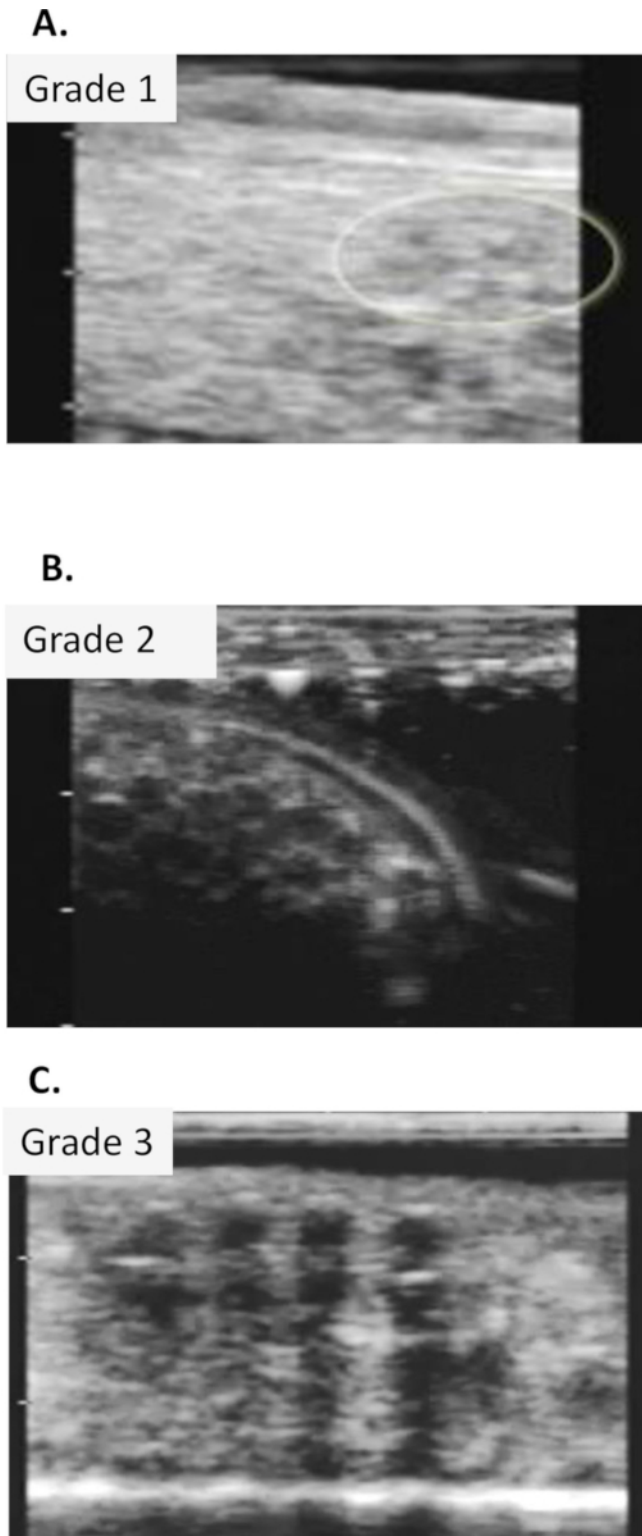


**Figure 4: Characterizing reproductive behaviors leading up to oviposition in *R. muscosa*** (A) courting. (B) Amplexus. (C) Male squeezing female while in amplexus. (D, E) Amplexed female in a hand-stand. (F, G) Abdominal contractions and oviposition. [Please click here to view a larger version of this figure.](#)

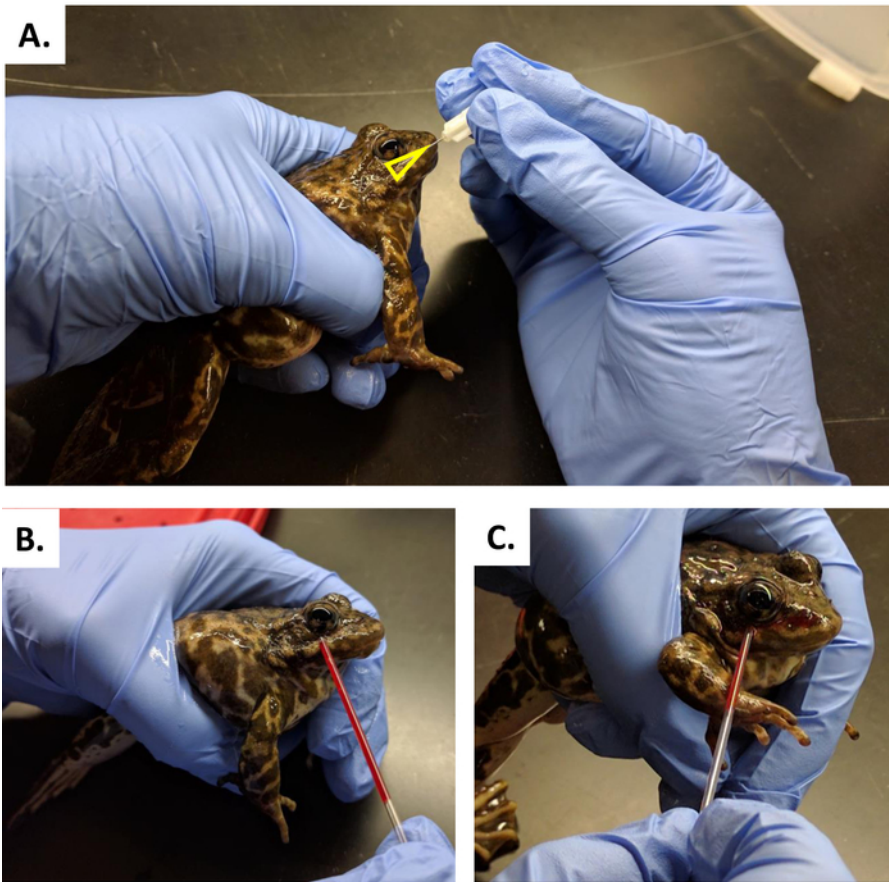




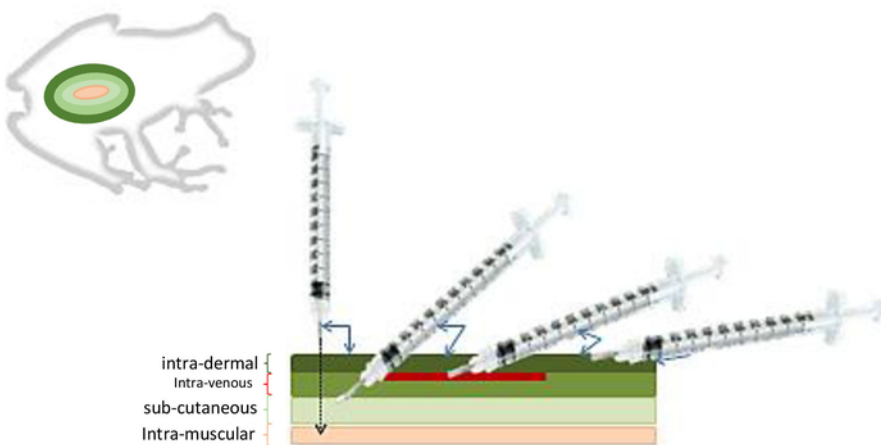
**Figure 5: Ultrasound performed on *R. muscosa* A-B with reproductive status according to developmental stage<sup>4</sup>.** (A, B) Performing ultrasound on *Rana muscosa*. (C) Grade 0. (D) Grade 1. (E) Grade 2. (F) Grade 3. (G) Grade 4 (ovulated and retained eggs) [Please click here to view a larger version of this figure.](#)



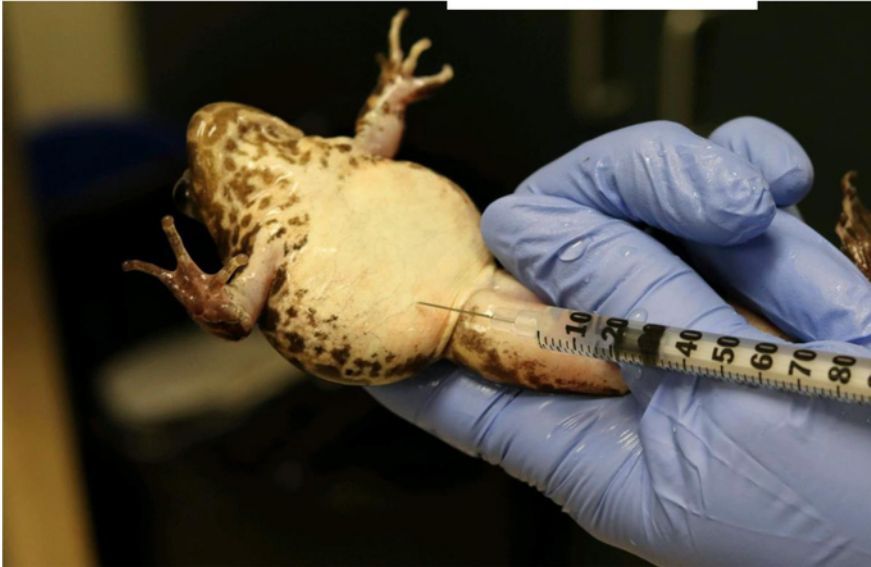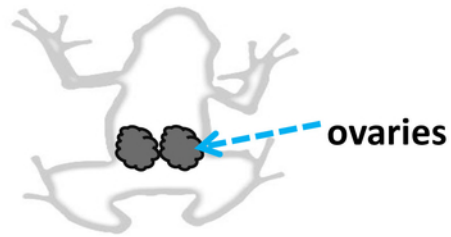
**Figure 6: Ultrasound images of *Necturus*. (A) Grade 1. (B) Grade 2. (C) Grade 3 eggs. [Please click here to view a larger version of this figure.](#)**



**Figure 7: Blood collection in *R. muscosa*.** (A) Blood collection by puncturing the vena orbitalis posterior the facial vein just above the jawline at the middle of the orbit. (B, C) Blood is released onto the skin's surface and is collected with a heparinized capillary tube. [Please click here to view a larger version of this figure.](#)

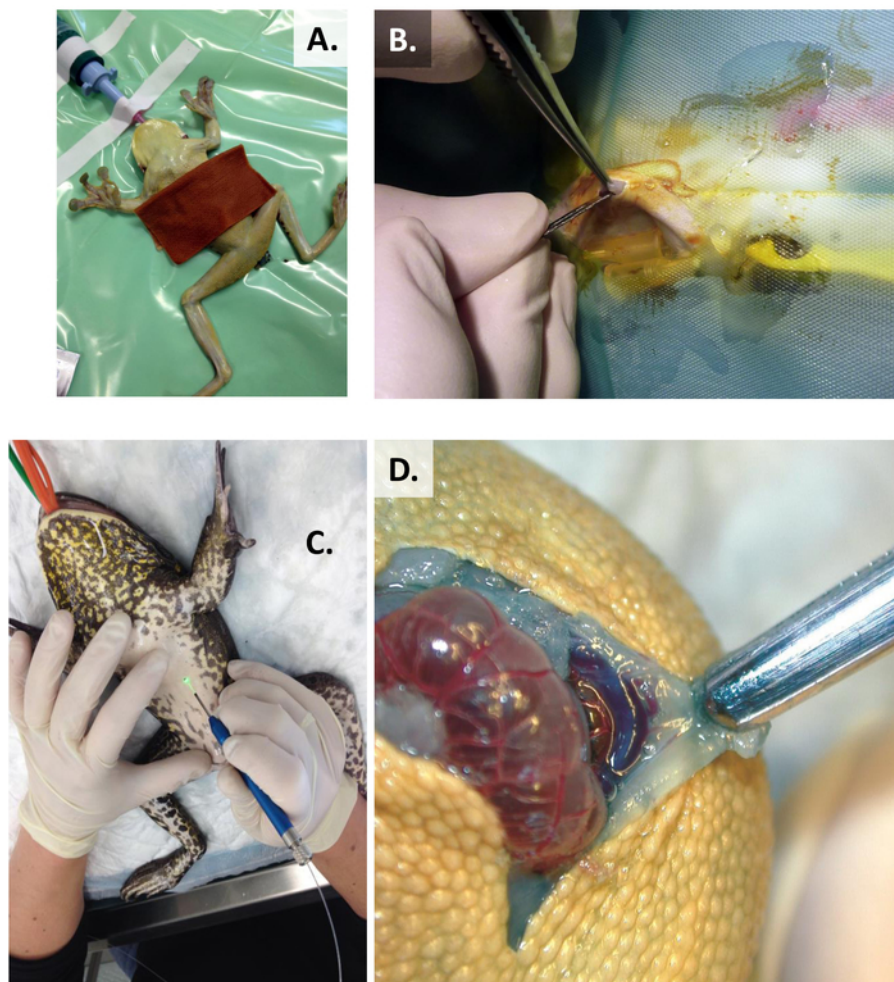


**Figure 8: Injection methods in amphibians.** Depending on the depth of the type of injection the angle and depth of the needle will vary. [Please click here to view a larger version of this figure.](#)

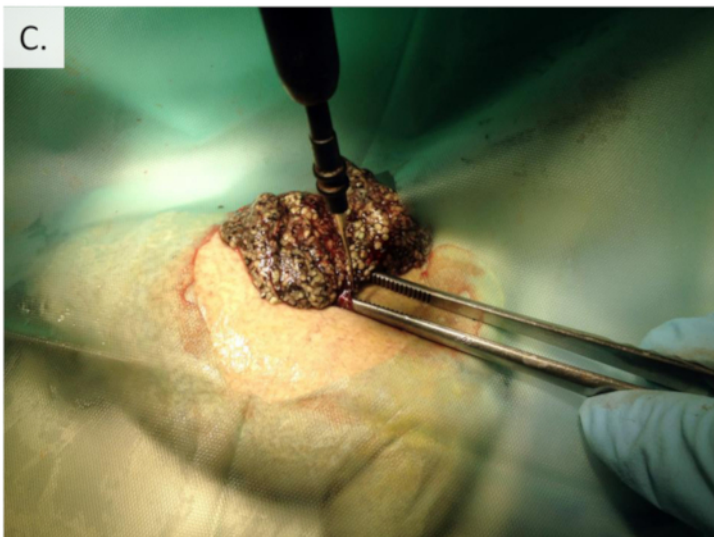
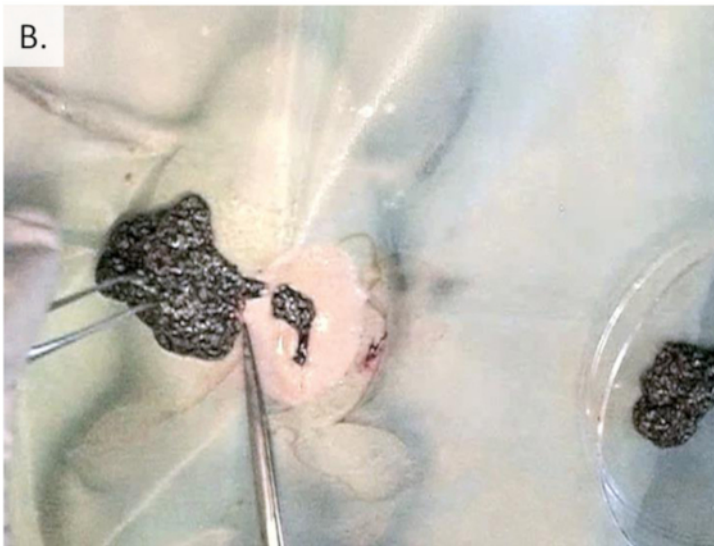
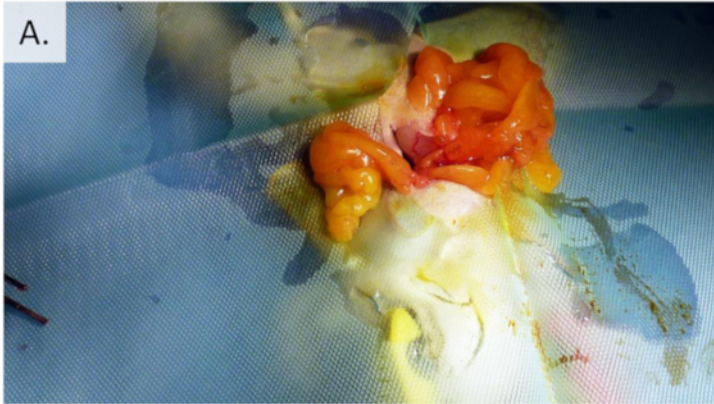

**Figure 9: Hormonal injection in *R. muscosa*.** Induction of oviposition by hormonal treatment in *Rana muscosa* females injected with amphiplex intra-peritoneally. Ovaries can be found in the coelomic cavity [Please click here to view a larger version of this figure.](#)



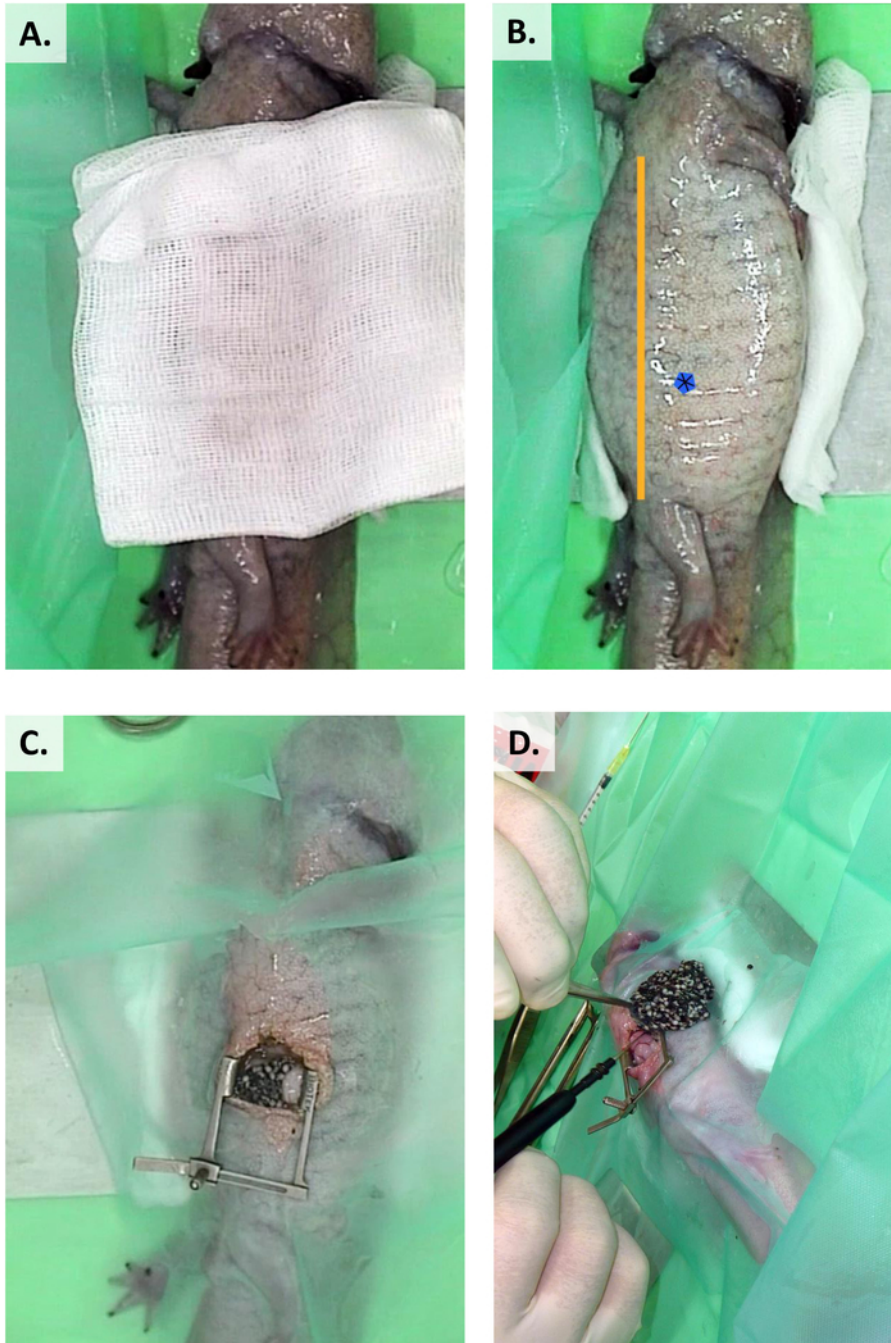


**Figure 10: Preparation before the surgery.** (A) Aseptic preparation of the surgical area using dilute povidone-iodine solution (1/10), *Trachycephalus resinifictrix*. (B) Clean scalpel incision in a *Xenopus laevis* or, (C) laser-diode skin incision, *Lithobates catesbeianus*. (D) Avoid damaging the mid-ventral vein, *Trachycephalus resinifictrix*. [Please click here to view a larger version of this figure.](#)

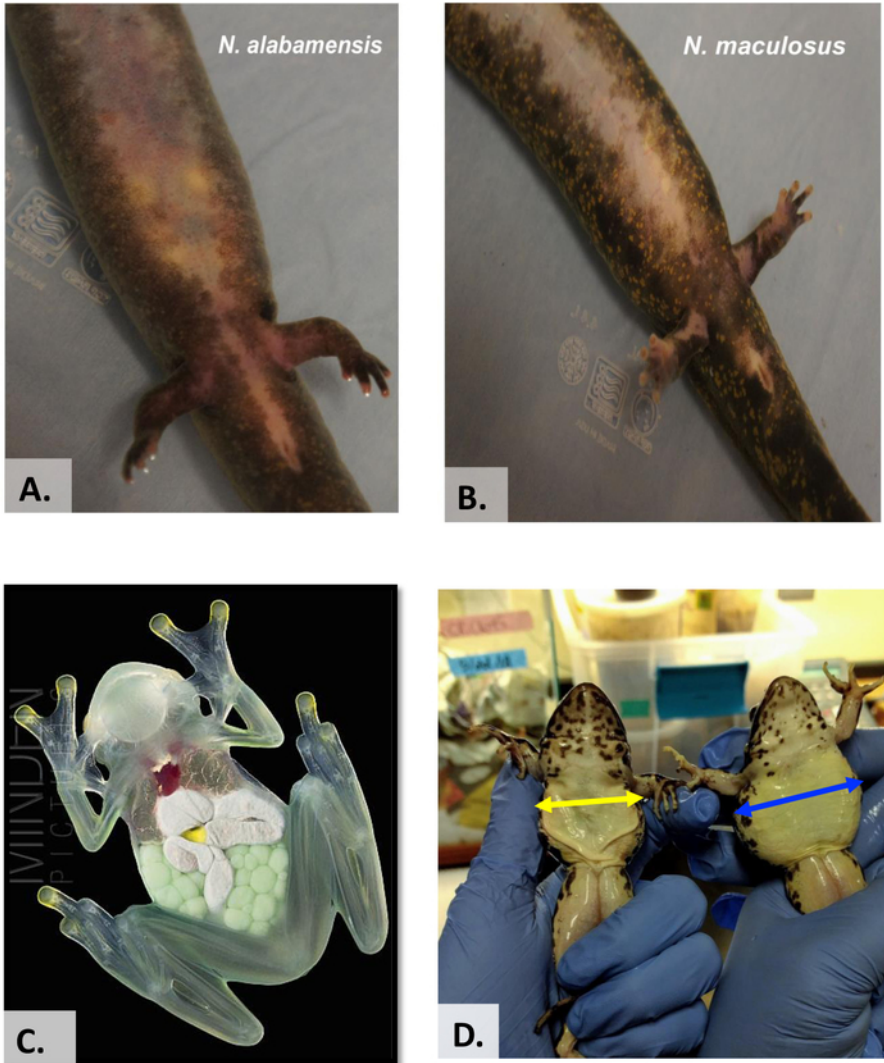


**Figure 11: Ovariectomy in *Xenopus laevis*.** (A) Expose and move large fat bodies to uncover the egg mass. (B) Excise a portion of egg mass without ligating any blood vessels. (C) Cauterize surrounding blood vessels by electrocautery for complete ovariectomy. [Please click here to view a larger version of this figure.](#)



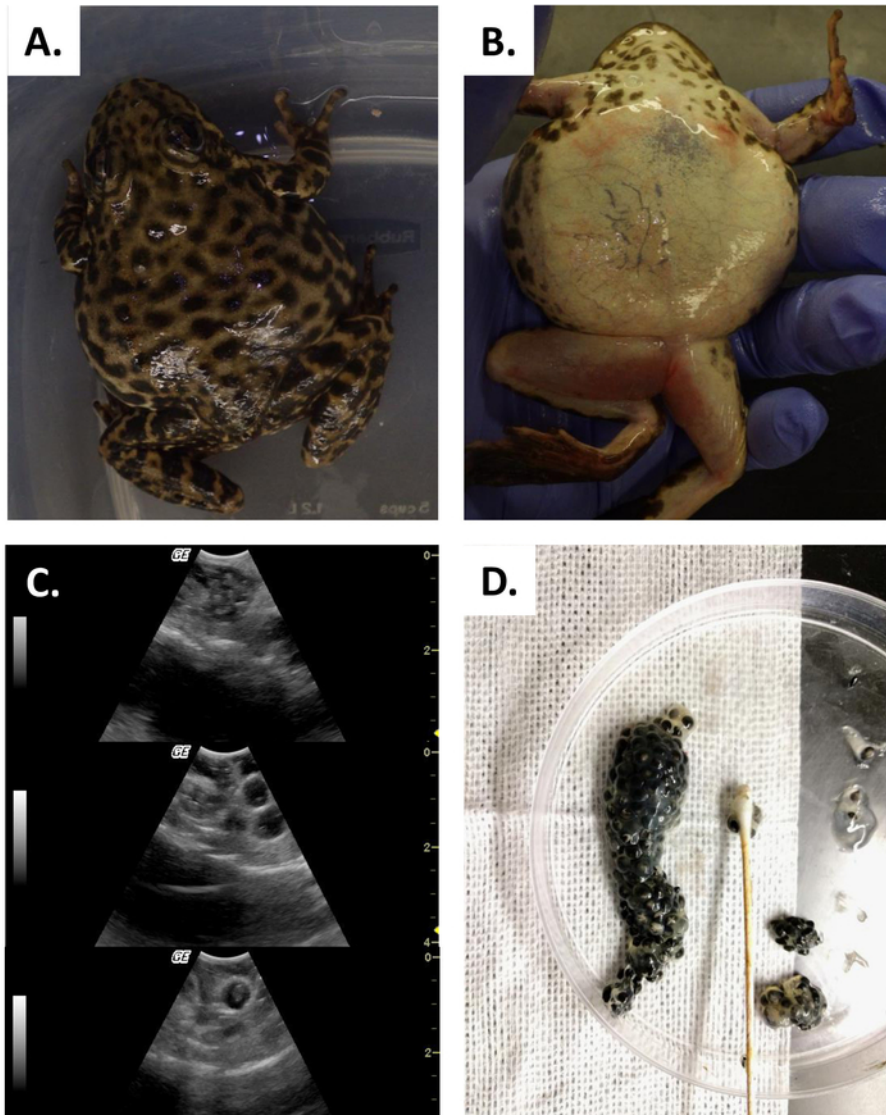


**Figure 12: Pre-surgical preparation and ovariectomy in *A. mexicanum*.** (A) Sterile gauze soaked in 0.75% chlorhexidine solution applied to the surgical site (B). A line between the shoulder and the hind limbs divides the animal into three equal parts and the blue spot marks the site on incision. (C) Retract the coelomic incisions with eyelid retractors. (D) For complete ovariectomy, cauterize the surrounding blood vessels by electrocautery. [Please click here to view a larger version of this figure.](#)



Glass frog image by Pate  
Oxford – Minden  
Pictures

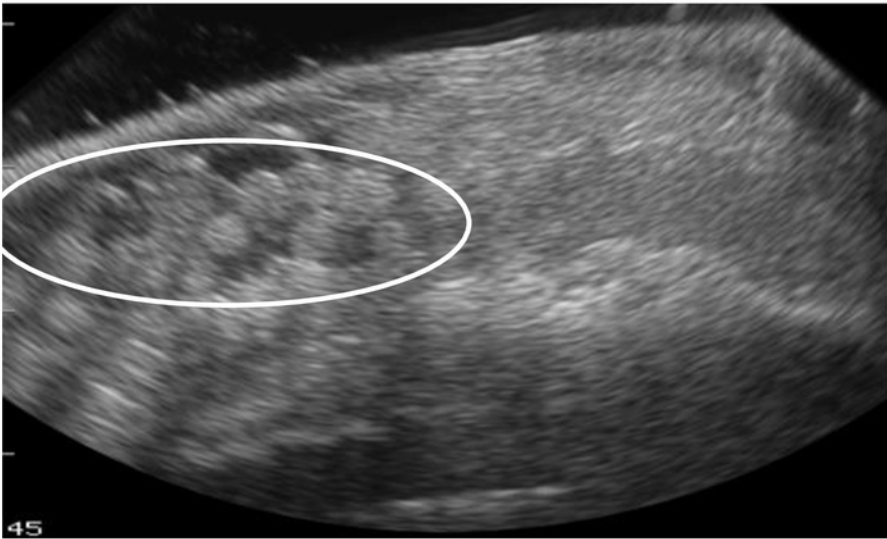**Figure 13: Visual Assessment of reproductive stages.** (A, B) Visual assessments of reproductive stage through semi-translucent skin, *Necturus*. (C) Translucent skin, *Hyalinobatrachium* (Glass frog). (D) Visual assessment of *R. muscosa* before (right, blue line) and after oviposition (left - yellow line). [Please click here to view a larger version of this figure.](#)



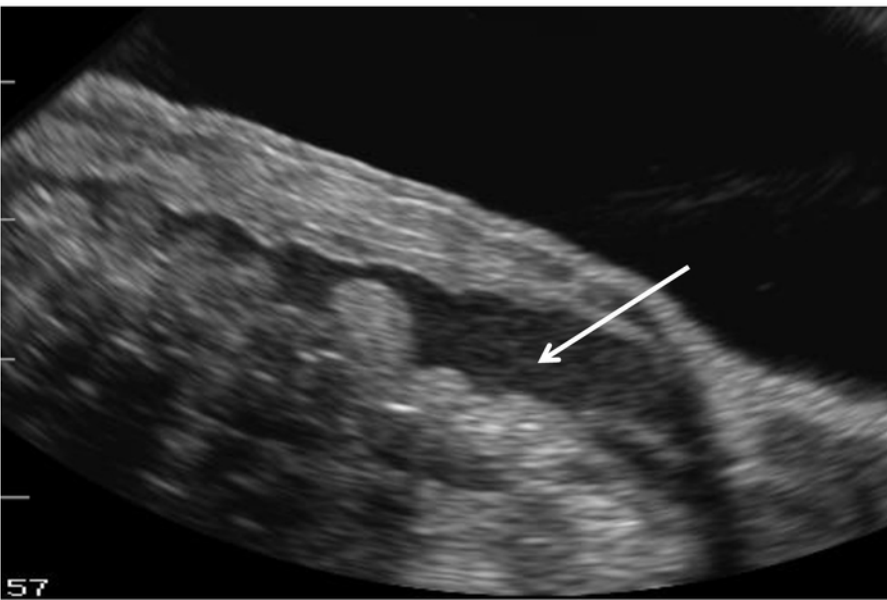**Figure 14: Egg retention.** (A, B) Female *Rana muscosa* with severe case of egg retention. (C) Ultrasound shows old degenerating, eggs (top) and larger eggs (middle and bottom panel) ovulated and trapped in the coelom. (D) Retained eggs retrieved by manual stripping. [Please click here to view a larger version of this figure.](#)



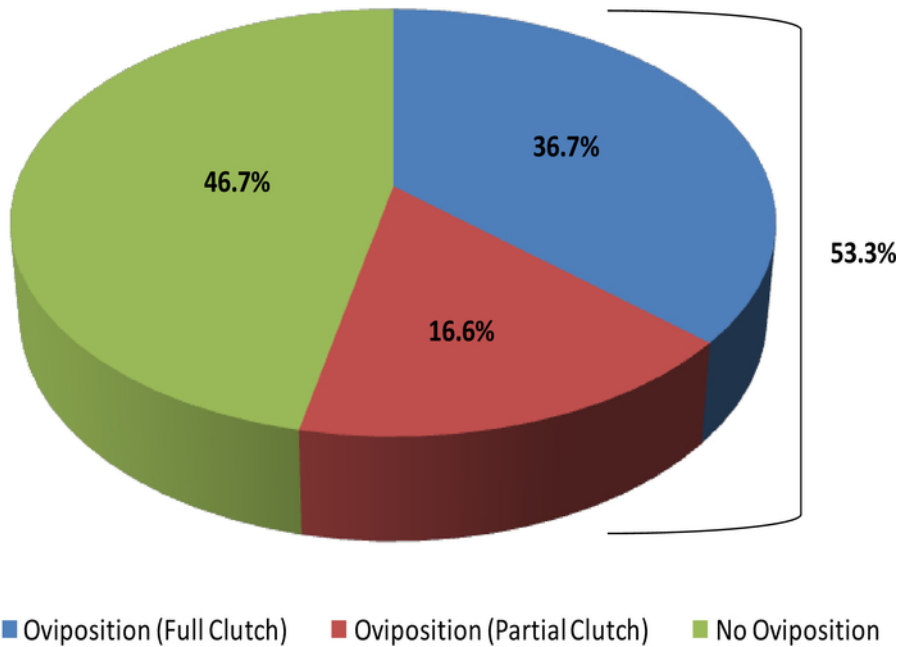
A.



B.



**Figure 15: Ultrasound images of retained eggs in *Necturus* that (A) became echogenic in appearance (circle) and were associated with (B) fluid retention in the body cavity (arrow). [Please click here to view a larger version of this figure.](#)**



■ Oviposition (Full Clutch) ■ Oviposition (Partial Clutch) ■ No Oviposition  
**Figure 16: Percentage of captive female *Necturus* that oviposited full or partial clutches (2013-2017) compared to those that did not oviposit. Please click here to view a larger version of this figure.**

## Discussion

Direct handling, visual observation and morphometric measures provide non-invasive techniques and are the first assessment criteria for determining female reproductive stage. However, this study shows that gravid ovaries cannot always be reliably identified by palpation. Depending on the species, gravid ovaries can sometimes be visually detected through semi-translucent (**Figure 13A, B**) or completely translucent skin on the ventral side of the animal (**Figure 13C**). Females that have completed oviposition can show obvious changes to their appearance compared to gravid females (e.g., loose skin and loss of up to 30% of their body mass, **Figure 13D**). During breeding, males and females will display certain behaviors that provide information about proximity to ovulation and oviposition. In the case of *R. muscosa* indications that a female is close to oviposition begin with the female entering handstands.

The application of ultrasound technology to Anurans and Caudates permits the diagnosis of presence or absence of eggs and whether oviposition was associated with complete or partial release of developed eggs. Thus, this method provides a more complete and accurate assessment of reproductive status without being limited to determining gravid/non-gravid status via a visualization technique that varies by abdominal skin transparency, or epidermal consistency among the different amphibian species. Ultrasound can be performed with relative ease and with little stress to the animals (**Figure 5** and **Figure 13**) and can be used to characterize reproductive cycles and to determine reproductive status<sup>4</sup>. It is critical to become familiar with the species; however, this study showed that *Necturus* and *R. muscosa* share common developmental signs in their reproductive patterns allowing for similar classification of reproductive stage (**Figure 5**). Through this technology there is now evidence that egg development is high in captive *Necturus* and *R. muscosa* and that both these species follow a seasonal pattern. Although the reasons for these phenomena are unknown and require further inquiry, without the use of ultrasound, several areas of ovarian dysfunction, such as egg retention and partial oviposition, would have gone undetected. Future applications to this technique will be used to determine whether females should be selected for breeding in any given year and whether oviposition is complete.

A blood collection protocol, such as that presented in *R. muscosa*, which is both effective and causes minimal distress to the animal, is optimal to study hormone profiles in captive and wild-caught Anurans (Calatayud, unpublished). To date, no information exists regarding the annual hormone profiles of captive *R. muscosa* and, therefore, no knowledge on how hormones are influencing their health and reproduction. Moreover, with evidence that females of this species may not be annual breeders, hormonal profiling will be another method for tracking ovarian cycles. Together with ultrasound, hormone analysis may lead to better prediction of what females will be ready for oviposition. Furthermore, in the past year, two cases of intersex in the captive *R. muscosa* population have been documented. In addition, the development of thumb pads has been noted on some of the older founding females. Reasons for this are currently under investigation but initial results suggest it may relate to changes in testosterone levels (Calatayud, unpublished). Discerning hormonal cycles in females of different ages will help us understand why females may develop male-associated secondary sexual characteristics and whether this is to be expected in an aging population.

Exogenous hormone therapy has been used to overcome reproductive dysfunctions frequently encountered in captive amphibians. However, for both *R. muscosa* and *Necturus* populations in this study, no significant differences in oviposition between hormone-treated and control females were detected over a 2 and 5-year period of time, respectively. This may indicate that hormone administration protocol, doses, priming and hormone combination used was not adequate for the species. Closer analysis of individual female reproductive histories suggests *R. muscosa* may not experience annual breeding, which could also account for the lack of hormonal-effect observed in treated females. Because a certain percentage of females consistently skipped breeding every year, understanding the natural history of the species can help determine whether there is a need for exogenous hormones and when they may be most effective. The procedures outlined in this article can be applied to a number of species, (**Table 1**) and are for anurans ranging from 5 g to 150 g; larger animals may require different syringes and needle gauges.

The location of the injection varies with some hormones requiring intra-muscular, intra-peritoneal, sub-cutaneous or intradermal injection (Figure 7).

Surgery for the purpose of ovariectomy is a common method used in various amphibian species to obtain oocytes for embryological studies. Ovariectomy may also be indicated for population control and medical issues such as egg retention. In the case of partial ovariectomies in which, oocyte harvesting is performed for research purposes, surgery must ensure that the animal remains reproductive. Administration of PGF<sub>2α</sub> has shown some promise in resolving egg retention in female *R. muscosa*. In several individuals, PGF<sub>2α</sub> elicited complete deposition of previously retained eggs but in others only partial deposition occurred requiring manual stripping to remove all the eggs. While PGF<sub>2α</sub> may serve as an alternative to surgery for egg retention in *R. muscosa*, its ability to remedy similar pathologic conditions in other amphibians will require species-specific validation. When surgical intervention is mandated for the Anuran or Caudate patient, it is necessary to ensure an adequate plane of anesthesia before incisions are made. Astute observation skills are needed to assess and monitor the normative induction and recovery responses as outlined in this study for each of the taxa. Once one is familiar with the specific anatomy, an appropriate surgical approach, hemostasis, gentle tissue manipulation and adequate postoperative management, reproductive surgeries pose no overwhelming obstacles.

## Disclosures

The authors have nothing to disclose.

## Acknowledgments

Natalie Calatayud would like to thank Dr. Barbara Durrant for training and assistance with ultrasound and to Exploradora de Inmuebles, S.A. (EISA) for awarding financial aid to my research associate position at SDZG. Thanks to Dr. Kylie Cane for comments on the manuscript as well as to the official reviewers (whoever they may be). Thanks to Jonathan Dain our 2018 Summer Fellow, San Diego Zoo Institute for Conservation Research for providing photos (Figure 1A,B). Monica Stoops extends appreciation to the Association of Zoos and Aquariums Conservation Endowment Fund and the Disney Worldwide Conservation Fund for providing financial support to establish the captive *Necturus* population. Additionally, support was also received through private donations from amphibian advocate Ms. Iris de la Motte. Thanks, is given to Mr. Christopher DeChant and Dr. Mark Campbell for their significant contribution to the research.

## References

1. Conde, D.A., Flesness, N., Colchero, F., Jones, O.R., Scheuerlein, A. An emerging role of zoos to conserve biodiversity. *Science*. **331** (6023), 1390-1391 (2011).
2. Conde, D.A. et al. Zoos through the Lens of the IUCN Red List: A Global Metapopulation Approach to Support Conservation Breeding Programs. *PLoS ONE*. **8** (12), e80311 (2013).
3. Morrison, C., Hero, J.-M. Geographic variation in life-history characteristics of amphibians: a review. *Journal of Animal Ecology*. **72** (2), 270-279 (2003).
4. Calatayud, N.E., Stoops, M., Durrant, B.S. Ovarian control and monitoring in amphibians. *Theriogenology*. **109**, 70-81 (2018).
5. National Research Council. *Institutional Animal Care and Use Committee Guidebook*. (2010).
6. Peig, J., Green, A.J. New perspectives for estimating body condition from mass/length data: the scaled mass index as an alternative method. *Oikos*. **118** (12), 1883-1891 (2009).
7. Graham, K.M., Langhorne, C.J., Vance, C.K., Willard, S.T., Kouba, A.J. Ultrasound imaging improves hormone therapy strategies for induction of ovulation and in vitro fertilization in the endangered dusky gopher frog (*Lithobates sevosus*). *Conservation Physiology*. **6** (1), coy020 (2018).
8. Wright, K.M., Whitaker, B.R. *Amphibian Medicine and Captive Husbandry*. Krieger Publishing Company. (2001).
9. Forzán, M.J., Vanderstichel, R.V., Ogbuah, C.T., Barta, J.R., Smith, T.G. Blood collection from the facial (maxillary)/musculo-cutaneous vein in true frogs (family Ranidae). *Journal of Wildlife Diseases*. **48** (1), 176-180 (2012).
10. Allender, M.C., Fry, M.M. Amphibian hematology. *Veterinary Clinics of North America: Exotic Animal Practice*. **11** (3), 463-480 (2008).
11. Green, S.L., Parker, J., Davis, C., Bouley, D.M. Ovarian hyperstimulation syndrome in gonadotropin-treated laboratory South African clawed frogs (*Xenopus laevis*). *Journal of the American Association for Laboratory Animal Science*. **46** (3), 64-67 (2007).
12. Jørgensen, C.B. External and internal control of patterns of feeding, growth and gonadal function in a temperate zone anuran, the toad *Bufo bufo*. *Journal of Zoology*. **210** (2), 211-41 (1986).
13. Jørgensen, C.B. Growth and reproduction. *Environmental Physiology of the Amphibians*. 439-466 (1992).
14. Vu, M., Trudeau, V.L. Neuroendocrine control of spawning in amphibians and its practical applications. *General and Comparative Endocrinology*. **234**, 28-39 (2016).
15. Clulow, J., Trudeau, V.L., Kouba, A.J. Amphibian declines in the twenty-first century: why we need assisted reproductive technologies. *Reproductive Sciences in Animal Conservation*. 275-316 (2014).
16. Kouba, A. et al. Assisted reproductive technologies (ART) for amphibians. *Amphibian Husbandry Resource Guide*. **2**, 60-118 (2012).
17. Clulow, J. et al. Optimisation of an oviposition protocol employing human chorionic and pregnant mare serum gonadotropins in the Barred Frog *Mixophyes fasciolatus* (Myobatrachidae). *Reproductive Biology and Endocrinology*. **10** (1), 60 (2012).
18. Browne, R.K., Seratt, J., Vance, C., Kouba, A. Hormonal priming, induction of ovulation and in-vitro fertilization of the endangered Wyoming toad (*Bufo baxteri*). *Reproductive Biology and Endocrinology*. **4** (1), 34 (2006).
19. Calatayud, N.E. et al. A hormone priming regimen and hibernation affect oviposition in the boreal toad (*Anaxyrus boreas boreas*). *Theriogenology*. **84** (4), 600-607 (2015).
20. Stoops, M.A., Campbell, M.K., Dechant, C.J. Successful captive breeding of *Necturus beyeri* through manipulation of environmental cues and exogenous hormone administration: a model for endangered *Necturus*. *Herpetological Review*. **45** (2), 251-256 (2014).



21. Mc Creery, B.R., Licht, P. Induced ovulation and changes in pituitary responsiveness to continuous infusion of gonadotropin-releasing hormone during the ovarian cycle in the bullfrog, *Rana catesbeiana*. *Biology of Reproduction*. **29** (4), 863-871 (1983).
22. Johnson, C.J., Vance, C.K., Roth, T.L., Kouba, A.J. Oviposition and ultrasound monitoring of American toads (*Bufo americanus*) treated with exogenous hormones. *Proceedings of the American Association of Zoo Veterinarians*. **299**, 301 (2002).
23. Herbert, D. *Studies of assisted reproduction in the spotted grass frog *Limnodynastes tasmaniensis*: ovulation, early development and microinjection (ICSI)*. (2004).
24. Michael, S.F., Buckley, C., Toro, E., Estrada, A.R., Vincent, S. Induced ovulation and egg deposition in the direct developing anuran *Eleutherodactylus coqui*. *Reproductive Biology and Endocrinology*. **2**, 6 (2004).
25. Ogawa, A., Dake, J., Iwashina, Y., Tokumoto, T. Induction of ovulation in *Xenopus* without hCG injection: the effect of adding steroids into the aquatic environment. *Reproductive Biology and Endocrinology*. **9** (1), 11 (2011).
26. Silla, A.J. Effects of luteinizing hormone-releasing hormone and arginine-vasotocin on the sperm-release response of Günther's Toadlet, *Pseudophryne guentheri*. *Reproductive Biology and Endocrinology*. **8** (1), 139 (2010).
27. Trudeau, V.L. et al. Hormonal induction of spawning in 4 species of frogs by coinjection with a gonadotropin-releasing hormone agonist and a dopamine antagonist. *Reproductive Biology and Endocrinology*. **8** (1), 36 (2010).
28. Krause, E.T., von Engelhardt, N., Steinfartz, S., Trosien, R., Caspers, B.A. Ultrasonography as a minimally invasive method to assess pregnancy in the fire salamanders (*Salamandra salamandra*). *Salamandra*. **49**, 211-214 (2013).
29. Browne, R.K., Li, H., Seratt, J., Kouba, A. Progesterone improves the number and quality of hormone induced Fowler toad (*Bufo fowleri*) oocytes. *Reproductive Biology and Endocrinology*. **4** (1), 3 (2006).
30. Bramucci, M. et al. Different modulation of steroidogenesis and prostaglandin production in frog ovary in vitro by ACE and ANG II. *American Journal of Physiology-Regulatory, Integrative and Comparative Physiology*. **273** (6), R2089-R2096 (1997).
31. Gobbetti, A., Zerani, M. Possible roles for prostaglandins E2 and F2 $\alpha$  in seasonal changes in ovarian steroidogenesis in the frog (*Rana esculenta*). *Journal of Reproduction and Fertility*. **98** (1), 27-32 (1993).
32. Gobbetti, A., Zerani, M., Carnevali, O., Botte, V. Prostaglandin F2 $\alpha$  in female water frog, *Rana esculenta*: Plasma levels during the annual cycle and effects of exogenous PGF2 $\alpha$  on circulating sex hormones. *General and Comparative Endocrinology*. **80** (2), 175-180 (1990).
33. Guillette Jr, L.J., Dubois, D.H., Cree, A. Prostaglandins, oviducal function, and parturient behavior in nonmammalian vertebrates. *American Journal of Physiology-Regulatory, Integrative and Comparative Physiology*. **260** (5), R854-R861 (1991).
34. Clulow, J., Mahony, M., Browne, R., Pomeroy, M., Clark, A. Applications of assisted reproductive technologies (ART) to endangered anuran amphibians. *Declines and Disappearances of Australian Frogs*. (Ed. A. Campbell.) pp. 219-225 (1999).
35. Browne, R.K., Wolfram, K., García, G., Bagaturov, M.F., Pereboom, Z. Zoo-based amphibian research and conservation breeding programs. *Amphibian and Reptile Conservation*. **5** (3), 1-14 (2011).
36. Chai, N. Surgery in amphibians. *Veterinary Clinics: Exotic Animal Practice*. **19** (1), 77-95 (2016).
37. Gentz, E.J. Medicine and surgery of amphibians. *Ilar Journal*. **48** (3), 255-259 (2007).
38. Snyder, W.E., Trudeau, V.L., Loskutoff, N.M. 168 a noninvasive, transdermal absorption approach for exogenous hormone induction of spawning in the northern cricket frog, *Acris crepitans*: a model for small, endangered amphibians. *Reproduction, Fertility and Development*. **25** (1), 232-233 (2012).
39. Kouba, A.J. et al. Emerging trends for biobanking amphibian genetic resources: the hope, reality and challenges for the next decade. *Biological Conservation*. **164**, 10-21 (2013).
40. Michael, S.F., Buckley, C., Toro, E., Estrada, A.R., Vincent, S. Induced ovulation and egg deposition in the direct developing anuran *Eleutherodactylus coqui*. *Reproductive Biology and Endocrinology*. **2** (1), 6 (2004).
41. Fort, D.J. *Frog reproduction and development study 2000 rana pipiens reproduction and development study*. Environmental Protection Agency (2003).
42. Clulow, J. et al. Differential success in obtaining gametes between male and female Australian temperate frogs by hormonal review: A Review. *General and Comparative Endocrinology*. **265**, 141-148 (2018).
43. Trotter, T.M., Armstrong, J.B. Diploid gynogenesis in the Mexican axolotl. *Genetics*. **83** (4), 783-792 (1976).
44. Marcec, R.M. *Development of assisted reproductive technologies for endangered North American salamanders*. Mississippi State University. (2016).
45. Wright, M.L. Melatonin, diel rhythms, and metamorphosis in anuran amphibians. *General and Comparative Endocrinology*. **4** (2002).